

THE UNIVERSITY OF NEW MEXICO
COLLEGE OF PHARMACY
ALBUQUERQUE, NEW MEXICO

The University of New Mexico

Correspondence Continuing Education Courses
for
Nuclear Pharmacists and Nuclear Medicine Professionals

VOLUME III, NUMBER 1

*Radiopharmaceuticals for the Diagnosis
of
Psychiatric Illness*

by:

Margo J. Muniz, R.Ph.

Co-sponsored by:

mpi
pharmacy services inc
an Amersham company



The University of New Mexico College of Pharmacy is approved by the American Council on Pharmaceutical Education as a provider of continuing pharmaceutical education. Program No. 180-039-93-006. 2.5 Contact Hours or .25 CEU's

**Radiopharmaceuticals for the Diagnosis
of
Psychiatric Illness**

by:

Margo J. Muniz, R.Ph.

Editor

and

Director of Pharmacy Continuing Education

William B. Hladik III, M.S., R.Ph.
College of Pharmacy
University of New Mexico

Associate Editor

and

Production Specialist

Sharon I. Ramirez, Staff Assistant
College of Pharmacy
University of New Mexico

While the advice and information in this publication are believed to be true and accurate at press time, neither the author(s) nor the editor nor the publisher can accept any legal responsibility for any errors or omissions that may be made. The publisher makes no warranty, express or implied, with respect to the material contained herein.

Copyright 1994
University of New Mexico
Pharmacy Continuing Education
Albuquerque, New Mexico

RADIOPHARMACEUTICALS FOR THE DIAGNOSIS OF PSYCHIATRIC ILLNESS

STATEMENT OF OBJECTIVES

The goal of this correspondence course is to increase the reader's knowledge of current applications and research in the assessment of psychiatric disorders using nuclear medicine techniques. This continuing education lesson is intended for nuclear pharmacists and nuclear medicine professionals who have an interest in the relationship between brain physiology and psychiatric disorders.

Upon successful completion of this material the reader should be able to:

1. Discuss general aspects of brain anatomy.
2. Compare and contrast structural imaging modalities and functional imaging modalities.
3. Develop a familiarity with radionuclides utilized in positron emission tomography (PET) brain imaging.
4. Develop a familiarity with single photon emission computed tomography (SPECT) brain imaging radiopharmaceuticals currently being used in the assessment of psychiatric illness.
5. Discuss the current status of nuclear medicine brain imaging.
6. Cite new developments in nuclear medicine brain imaging.
7. Identify current and potential roles of nuclear medicine brain imaging in the following disease states:
 - a. Alzheimer's Disease
 - b. Depression and Affective Disorders
 - c. Obsessive-Compulsive Disorder
 - d. Schizophrenia

COURSE OUTLINE

RADIOPHARMACEUTICALS FOR THE DIAGNOSIS OF PSYCHIATRIC ILLNESS

- I. INTRODUCTION
- II. ANATOMY OF THE HUMAN BRAIN
- III. BLOOD BRAIN BARRIER
- IV. STRUCTURAL IMAGING MODALITIES
- V. FUNCTIONAL IMAGING MODALITIES
 - A. Physiological Imaging with PET
 - i. Procedure Discussion
 - ii. PET Radiopharmaceuticals
 - iii. PET Procedures: Assets and Liabilities
 - B. Physiological Imaging with SPECT
 - i. Procedure Discussion
 - ii. SPECT Radiopharmaceuticals
 - iii. SPECT Procedure: Assets and Liabilities
- VI. CURRENT APPLICATIONS IN PSYCHIATRY
 - A. Alzheimer's Disease and the Dementias
 - i. Disease Overview
 - ii. Diagnostic Accuracy
 - iii. Structural Imaging
 - iv. Functional Imaging
 - B. Depression
 - i. Disease Overview
 - ii. PET Imaging
 - iii. SPECT Imaging
 - C. Obsessive-Compulsive Disorder (OCD)
 - i. Disease Overview
 - ii. PET Imaging
 - iii. SPECT Imaging
 - D. Schizophrenia
 - i. Disease Overview
 - ii. PET Imaging
 - iii. SPECT Imaging
- V. CONCLUSION

by:

Margo Muniz, R.Ph.
Honors Program
Problem Based Learning Curriculum
Southern Illinois University Medical School
Carbondale, Illinois

INTRODUCTION

Functional brain imaging and its application in evaluating brain physiology, as it relates to psychiatric disorders, is advancing at a rapid pace. Over the last two decades, there has been a drive toward developing methods that provide better structural and functional assessments of the brain that are less invasive and more accurate. Current technologies for brain assessment are classified as either *structural* as in x-ray computed tomography (CT) and magnetic resonance imaging (MRI) or *functional* as in single photon emission computed tomography (SPECT) and positron emission tomography (PET) (1,2). The primary difference between an anatomic (structural) modality and a physiologic (functional) modality is that the anatomic scan can appear the same whether the patient is dead or alive (Fig 1, see Center Spread). Functional imaging, on the other hand, allows the psychiatrist to immediately view cerebral blood flow and metabolism (1). This emphasis on brain functioning provides a more objective measure of hypothesized brain abnormalities in psychiatric illness. Thus, nuclear medicine applications promise exciting and progressive advances for the field of psychiatry.

In this lesson, current brain imaging modalities will be examined along with some of their current and potential applications in psychiatric assessment. To help prepare for the following discussions, a review of brain anatomy, various imaging modalities, and some potential applications of these to clinical psychiatry, will be provided.

ANATOMY OF THE HUMAN BRAIN

The two components of the central nervous system are the *Brain* and the *Spinal Cord*. The brain possesses two symmetric hemispheres (left and right), which together make up the cerebrum. Each of the two hemispheres can be divided into the following lobes--frontal, parietal, temporal, occipital, insular and limbic. The cerebrum comprises the greater portion of

the brain mass and occupies the majority of the skull cavity. The cerebrum has an outer layer of *gray matter* which is composed of unmyelinated neurons. This layer is referred to as the cerebral cortex. Beneath the cortex lies tracts of fibers comprising the *white matter*, which are myelinated nerve fibers. Deep to the nerve fibers there are additional aggregates of neuronal cell bodies. These aggregates, known as basal ganglia, are involved in somatic (inhibitory) motor functions. Located in the posterior fossa, which is found dorsal and inferior to the cerebral hemispheres, is the smaller cerebellum. The cerebellum also contains two hemispheres and is primarily responsible for motor coordination and spacial orientation of the body. Medial to the cerebral hemispheres and extending towards the inferior, is the part of the brain referred to as the brainstem.

The superior-most structures of the brainstem are the thalamus and the closely positioned hypothalamus. The thalamus functions in the integration of sensory experiences resulting in proper motor responses. It also integrates sensory input with corresponding emotional responses and regulates the state of awareness (consciousness). The hypothalamus is located directly inferior to the thalamus and lies in the floor of the fourth ventricle. The hypothalamus maintains neuronal connections with the frontal and temporal cortices, thalamus, and brainstem. The hypothalamus also is responsible for emotional behaviors, and regulation of the autonomic visceral nervous system. Finally, it integrates descending impulses related to both reflexive and skilled movements. Postero-inferior to the thalamus is the midbrain portion of the brainstem, then the pons, and lastly the medulla. The midbrain possesses several important control functions including autonomic reflexes associated with visual and auditory systems and movement patterns. The pons is located ventrally to the cerebellum and inferior to the midbrain and therefore forms a bridge whose primary function is to connect the cerebellum with the brainstem and the cerebrum. The medulla oblongata is a passageway composed of nerve fiber tracts that extend between the spinal cord and the higher regions of the brain. It contains reflex centers and the cranial nerve nuclei located throughout the brainstem.

The ventricles of the brain form a continuous fluid-filled system of spaces within the brain. The choroid plexus are networks of capillaries associated with the linings of the ventricles and are responsible for the production of cerebral spinal fluid (CSF). The CSF is a watery fluid with a composition similar to that of plasma. The CSF serves as a cushion for the entire central nervous system, protecting the delicate tissues from impact and damage (3-5).

BLOOD BRAIN BARRIER (BBB)

The blood brain barrier (BBB) is the principal governing mechanism of any sort of physiologic imaging. The BBB is an anatomic barrier, which is formed by endothelial cells of the capillary beds in the brain. The tight junctions and the plasma membrane of these endothelial cells combine to form this continuous physical barrier to intercellular diffusion of substances. This barrier is selective and is the primary determinant of what substances will enter the brain from the blood supply. There are many substances which, as a result, are restricted from entering the brain. Thus, some radiopharmaceuticals will be prohibited from entering the brain if the BBB is intact. However in many disease states, the BBB is compromised and, therefore, there is a significant display of radiotracer (3-7). In the case of psychiatric patients, without concomitant anatomic pathology, the radiotracer must be able to traverse the intact BBB in order to obtain useful images. Newer brain-imaging radiotracers, therefore, are usually lipophilic and of a small enough molecular weight to allow passive diffusion across the intact BBB.

STRUCTURAL IMAGING MODALITIES

X-ray computed tomography (CT) and magnetic resonance imaging (MRI) evaluate structure and not function, and thus are not generally utilized by themselves in the assessment of psychiatric disorders. However, when used in conjunction with SPECT or PET, they do possess a certain diagnostic utility (8). Structural imaging techniques can be combined with nuclear medicine evaluations to determine whether there are any variations between functional and anatomical aspects of the brain. In other words, the CT or MRI study can be utilized along with the nuclear medicine study to elucidate any structural changes and their corresponding or related functional deficits.

FUNCTIONAL IMAGING MODALITIES

Physiological Imaging with PET

Procedure Discussion. PET offers a method of studying the dynamics of cerebral glucose utilization and cerebral blood flow in the intact functioning human brain. The PET technique involves the merging of two very complex technologies. First, there is the generation of a positron emitting nuclide by an on-site cyclotron, which is then tagged to a suitable biologically active tracer and introduced into the cerebral circulation. Secondly, the distribution of the radiotracers in the various regions of the brain is assessed via computerized tomographic construction.

This data can then be used to determine the cerebral blood flow, metabolic activity, and other physiologic parameters of the functioning human brain.

The decay of a positron-emitting nuclide results in the release of a *positron*--a particle with a single excess positive charge. This particle will then travel through the tissue for only a few millimeters, before being captured by an electron with a single negative charge. This collision of oppositely charged particles results in the production of two gamma rays of equal energy (511 keV), which are released in opposite directions (2,9). (Fig 2, see Center Spread) The PET scanner detects the presence of the twin gamma rays when they hit the crystal in the detector to release fluorescent flashes of light. The scanner possesses paired detector heads which recognize and record any gamma emissions which occur on a *coincident line* (180 degrees). The computer assesses the time it takes for these two gamma rays, traveling in their 180 degree opposite trajectories, to simultaneously hit the detector, and determines where the gamma rays originated from in the tissue. These coincident events are measured on various tomographic planes, since paired detectors will only detect events occurring in the narrow slice of tissue between them. By utilizing a circular array of detector heads positioned around the organ of interest, a detailed tomographic representation of the pattern of radiotracer distribution can be determined. Thus PET is capable of producing a regional map of functional activity in a manner similar to the reconstruction of a structural brain image as performed by an x-ray CT scanner (9).

PET Radiopharmaceuticals. At present, there are several positron-emitting radiopharmaceuticals being utilized clinically. The most common clinical studies utilize F-18 labeled flurodeoxyglucose (FDG). Since the brain derives almost all of its energy from glucose, this technique is well suited to image alterations in regional cerebral metabolism. Radiolabeled FDG produces metabolites that are retained in the brain tissue for a prolonged period of time, which gives this compound a distinct advantage over radiolabeled glucose. Thus, FDG allows for an extended imaging time. Measurements can be made in the fasting patient within 40-120 minutes post-injection with F-18 FDG.

Another common PET radiopharmaceutical is water labeled with a positron-emitting isotope of oxygen (O-15). This radiotracer can be used to assess perfusion and blood volumes. Oxygen-15 is also used to radiolabel carbon monoxide and oxygen gas. Other radionuclides can be used to evaluate brain blood flow or the location, density, and activity level of a variety of receptors. The nuclides C-11, O-15, N-13, and F-18, are often incorporated into biological tracers used in PET imaging (2,10-12). Further discussions of PET

radipharmaeaceuticals may be found in Volume II, No 5 of this continuing education series ("Radiopharmaceuticals for Clinical PET: Formulation and Quality Control, Regulatory Issues, and Professional Responsibilities," Morlein SM, Welch MJ, Seigel, BA, 1993).

PET Procedures: Assets and Liabilities. There are several assets and liabilities related to the use of PET in the clinical setting. The first advantage is that PET is capable of attaining high resolution (down to 5mm). This is because the attenuating effect of the tissues can be regionally measured, thus allowing for appropriate corrections to be made (9). Secondly, PET can evaluate a very important metabolic process in the brain--that of glucose utilization. Much of the work done with PET allows the acquired information to be interpreted both qualitatively and quantitatively (2).

Table 1. Abbreviated list of compounds labeled with PET radionuclides*

PRIMARY APPLICATIONS LABELED COMPOUNDS

Cerebral Blood Flow	H ₂ ¹⁵ O, C ¹⁵ O ₂ , ¹¹ C-alcohols, ¹⁸ F-ethanol
Transport and Metabolism	
Oxygen	¹⁵ O ₂
Glucose and Metabolites	(¹⁸ F)2-deoxy-2-flouro-D-glucose, ¹¹ C-D-glucose, 2-(¹¹ C)-deoxy-D-glucose
¹³ N-labeled Amino Acids	L(¹³ N)-glutamate and l-glutamine alanine, aspartate, leucine, isoleucine, methionine
¹¹ C-labeled Amino Acids	L(¹¹ C)-aspartate, leucine, glutamate, valine, D,L(¹¹ C)-alanine, leucine, tryptophan, oxalacetate.
Receptors	
Dopamine	¹⁸ F-, ¹¹ C-spiperone, ¹⁸ F-haloperidol, ¹¹ C-L-DOPA
Benzodiazepine	¹¹ C-flunitrazepam, Diazepam, ¹⁸ F-valium
Cholinergic	¹¹ C-imipramine
Opiate	¹¹ C-ctorphine, N-methyl- ¹¹ C-morphine
Adrenergic	¹¹ C-norepinephrine, propranolol

* adapted from Phelps ME, et.al. (13)

Unfortunately, PET also has a number of liabilities. The radionuclides utilized in PET studies all have short half-lives. This fact necessitates the close proximity of

cyclotron to the imaging site. Due to the prohibitive costs of a cyclotron, PET studies are currently predominately performed at large academic centers which are able to shoulder this substantial expense. Cyclotron costs can vary from \$1,000,000 to \$2,000,000 (2). Because of the complex nature of cyclotron maintenance and operation, PET studies also require a large expenditure in terms of time and the cost related to training specialized technicians. These combined factors can result in a high cost per injection, ranging from \$2000 to \$10,000 (2,10). Therefore, the need for highly specialized technical support combined with the cost of facilities currently negates the use of PET imaging in routine clinical applications.

Physiologic Imaging with SPECT

Procedure Discussion. The term *single-photon emitting radionuclides* refers to all commercially available photon-emitting nuclides that emit only one photon per disintegration. Examples used in brain imaging include iodine-123, technetium-99m, and xenon-133. The term differentiates these radionuclides from the dual photon-emitting nuclides used in PET. As previously discussed, the technology used in PET is cumbersome and costly. For these reasons, there is great interest in developing the more widely-available and less expensive SPECT brain imaging techniques (14).

Table 2. Comparison of PET and SPECT Brain Imaging*

Variable	PET	SPECT
Sensitivity	Very High < 10 ^{-12M}	High < 10 ^{-11M}
Resolution of Commercial Devices	5-6mm	8-12mm
Commonly used Isotopes	O-15 C-11 F-18	I-123, Tc-99m, Xe-133
T _{1/2} of Nuclides	2, 20, 110 min	13, 6, 127 hours
Production of Radionuclides	On-site Cyclotron	Commercial supplier or simple on-site generator
Cost per Scan	\$1,500-10,000	\$25-400

* Adapted from Innis RB (10) and Schuckit MA (2)

The scanner used in SPECT detects light produced when gamma rays collide with a sodium iodide crystal. The energy of the gamma ray and the trajectory of the

incoming rays will be assessed by a computer which will then format the information into data regarding the original position of the scintillation. This data will be accumulated and used in forming tomographic image slices of the tissue in question.

A single head camera may be used which rotates around the patient's head. This approach enables the utilization of methods currently available in many hospital nuclear medicine departments. The single camera head is the least expensive SPECT imaging system, and can also be utilized for both SPECT applications and planar imaging techniques of other areas of the body (15,16).

Newer techniques involve the use of multiple camera heads in which two or more detectors are brought into close proximity of the patient's head. This approach results in greater resolution of images and decreases the scan time necessary for image acquisition. Multidetector SPECT cameras incorporate multiple detectors into a ring. As a result, there are no detector heads which revolve around the patient. Instead the patient is placed in a ring-shaped scanner for imaging. The array of detectors may either rotate or be in a stationary position as the information is gathered. These systems are very expensive, but have the advantage of excellent image resolution. Since the anatomic structures can be visualized with high accuracy, ring systems are particularly suited to comparisons with concomitant CT or MRI images (15-17).

Both single detectors and multidetector SPECT systems allow the development of image reconstruction in multiple orthogonal planes. For diagnostic clarity, current protocols require the acquisition of at least three orthogonal image planes (i.e., transaxial, coronal, and sagittal) (14,15,18).

SPECT Radiopharmaceuticals. The SPECT approach takes advantage of many commercially-available radiopharmaceuticals. The majority of SPECT brain imaging radiopharmaceuticals are cerebral blood flow (CBF) or perfusion agents (15). The first, Xe-133, has a long history of use as a two-dimensional CBF imaging agent (9,14). Radioactive xenon, a gas which has been solubilized in normal saline, is administered by intracarotid injection. This study is correlated with cerebral angiography for the purpose of identifying the blood vessels under study. Because of the ability of the lungs to rapidly remove the gas, a relatively large quantity can be injected without an excessive radiation dose, even when serial injections are performed [5 mCi every 10-15 min (maximum of five injections)]. Since the gas is administered via the carotid, the activity will localize in one hemisphere, allowing for a very high count rate for the two-dimensional (side view) technique. This

technique is traumatic to the patient, however, and has been largely abandoned, favoring newer noninvasive techniques. With the advent of computed tomography techniques and rotating camera heads, intraarterial injections have given way to inhalation techniques. Tomographic images are obtained using a four-camera system and Xe-133 which is admixed to air. The admixture should result in an alveolar concentration of about 10 mCi/liter per 1.5 minute inhalation. During the inhalation and for three one-minute periods thereafter, a series of four tomographic images is acquired. The entire procedure lasts less than five minutes and is completely atraumatic. CBF is obtained in three slices of brain tissue with corresponding blood flow calculations. Xenon, however, is not the ideal CBF SPECT agent. The gas has the disadvantages of a short shelf life (3-5 days) and poor image resolution due to its low energy gamma ray (81 keV), which is easily scattered in the brain tissue. (2,13,14,19).

A second frequently-used radiopharmaceutical is I-123 iodoamphetamine (iofetamine) (currently unavailable in the U.S.). This radiopharmaceutical has the advantage of a high energy gamma ray (159 keV), which results in a higher resolution image than that obtained with xenon. I-123 iofetamine is marketed in a prepared unit-dose vial, which allows for convenience in that the dose is already buffered and has undergone quality control testing by the manufacturer. I-123 iofetamine, however, is costly. In addition, this product has a physical half-life of 13 hours, which may serve as a potential disadvantage in that it must be ordered within 24 hours of its use. This agent is injected intravenously; it exhibits a high first pass extraction (approximately 90%) and brain uptake is reasonably constant between 20-60 minutes post injection. The distribution of I-123 iofetamine best correlates with rCBF at 13-27 minutes post injection (79) and, thus, imaging should be performed within 30 minutes following injection. The accessibility of I-123 iofetamine to areas of the brain affected by altered brain anatomy or changes in function are currently under further investigation (2,13,15,19,20).

The third frequently used brain imaging agent is hexamethylpropylene amine oxime (HMPAO), a technetium-99m labeled chelate, which readily crosses the BBB. The compound is a neutral, lipophilic complex which is used in rCBF assessment with SPECT. The generic name of this radiopharmaceutical is exametazime and it carries the trade name Ceretec® (Medi-Physics--an Amersham Company). It is currently the only lipophilic technetium brain imaging agent approved by the FDA (15).

Following intravenous injection, brain activity will peak within one minute, and will plateau at two minutes at about 88% of peak activity. Brain activity

remains relatively constant for several hours. Imaging with Tc-99m exametazime results in good differentiation between cerebral *grey matter* and cerebral *white matter*, with higher uptake in *grey matter*. Retention of the chelate is directly related to the glutathione concentrations in brain tissue.

This radiopharmaceutical has several advantages. The first of which is its long shelf life. Unlabeled exametazime can be stored for months and can be easily compounded with eluate from a small on-site commercial Mo-99/Tc-99m generator. Secondly, the radiolabeled product can be injected in much higher doses than Xe-133 or I-123 iofetamine. In addition, imaging may begin as early as 15 minutes post-injection. Ceretec® has a high extraction efficiency, resulting in good image quality. However, much as with I-123-iofetamine, further research is needed to allow for greater understanding of this drug's distribution within the brain of patients with various disease states (2,21,78).

Neuroreceptor imaging shows great promise in SPECT psychiatric scintillation studies. Brain receptors are probably more closely linked to the actual pathology of psychiatric disease than is glucose metabolism or blood flow. Neuroreceptor imaging is also significant since brain receptors are the mediators of the actions of most psychotropic drugs. Thus, neuroreceptor imaging may provide insight into psychiatric drug efficacy and pharmacokinetics. In the past, receptor studies have been principally performed using PET, but the advent of newer drugs such as I-123 iomazenil (Ro16-0154), a radioiodinated version of flumazenil (Romazicon®--Hoffman-LaRoche), a benzodiazepine receptor antagonist, will make receptor imaging more accessible to the clinical setting via SPECT (10,22).

SPECT Procedures: Assets and Liabilities. SPECT imaging offers many advantages for brain imaging relative to PET. The use of longer-lived radionuclides circumvents the requirement for an on-site cyclotron. SPECT is more affordable and less technically cumbersome. Newer drugs, improved equipment, availability for routine clinical use, and better imaging techniques are likely to give SPECT the advantage over PET in psychiatric applications.

CURRENT APPLICATIONS IN PSYCHIATRY

Alzheimer's Disease and the Dementias

Disease Overview. Dementia is defined as a deterioration from a previous level of intellectual functioning due to organic brain pathology. Symptoms include personality changes and deficits in short term memory, abstract thinking, judgement, and impulse control. Deficits in memory are often one of the first

symptoms to appear, with recent memory being worse than long-term memory. The dementia patient has difficulty learning new material and will minimize or deny these deficits. The disease may be chronic with a slow insidious onset as found with Alzheimer's or be acute as found in brain injury due to trauma or disease (77).

Alzheimer's disease is the most common of the dementias, accounting for at least 50 percent of all cases of hospital-reported dementia and 80 percent of community reports (23). According to current figures from the National Institute of Aging, Alzheimer's disease is the fourth leading cause of death in the United States. Alzheimer's disease, therefore, follows heart disease, cancers, and stroke in terms of yearly deaths attributable to disease. The costs associated with Alzheimer's disease is formidable. The current estimates for care and treatment are a staggering \$88 billion. In terms of health care cost, the figures makes Alzheimer's one of the most costly diseases in the country (24).

The progressive degenerative dementias (such as Alzheimer's disease), frontal lobe degeneration, and vascular dementia are often initially presented in the clinical setting as psychiatric changes. However, the patients develop the psychiatric symptoms as a result of brain degeneration that involves anatomic pathologies due to injury and/or degeneration of tissues in specific regions of the brain (24,25). Although CT and MRI have certain utility in the evaluation of progressive degenerative dementias, these modalities illustrate structural, not functional, changes in the brain. For example, CT scans in advanced cases of Alzheimer's may show marked sulcal widening, insular atrophy, and ventricular enlargement that are common findings in cases of brain atrophy (23,26). Physiological imaging techniques can then be used to evaluate the regional functional activity of the disease state. For instance, regional cerebral blood flow is coupled to changes in metabolic demand, and therefore any change in blood flow patterns may indicate variations in neuronal metabolism (27). By augmenting structural evaluations with functional brain imaging, there is a significant improvement in the accuracy of differential diagnosis of the dementias. Initial clinical studies have shown that patients with Alzheimer's disease and patients with multi-infarct dementia can be diagnosed with a high degree of accuracy (28-31).

Alzheimer's disease and Pick's disease are the two major degenerative diseases with a large cortical component. Their principal clinical expression is dementia. It is important to note that there are many other causes of dementia, such as cerebrovascular disease, encephalitis, hydrocephalus, and various metabolic diseases. For reasons discussed below, it is

important to make the proper diagnosis (24,30).

There are two common features that the degenerative diseases share: 1) They are diseases of neurons which selectively impact one or more systems of neurons and at the same time leave others intact. For example, in Alzheimer's disease there is a progressive devolution of the temporoparietal cortex, yet the visual cortex and motor sensory strip are almost entirely exempted. 2) Degeneration of the central nervous system structures is bilateral, symmetric and temporally progressive (26).

Diagnostic Accuracy. Approximately one-half of the patients presenting with the early clinical symptoms of dementia cannot be assessed in an accurate manner by current clinical criteria (28). Of these dementias, statistics show that the best institutions correctly diagnose only 80% to 90% of the Alzheimer's cases correctly. Of misdiagnosed patients, 1% to 2% have reversible diseases that could be treated (24). Thus, accurate diagnosis is extremely important because dementia-like symptoms may, in fact, be masking a condition that is treatable or even reversible. Examples include depression, which is a reversible disorder, and vascular dementia, which has a treatable component. Thus, proper and accurate diagnosis is extremely important in order to properly assess the patient in terms of both prognosis and treatment regimens.

Structural Imaging. The CT study can provide valuable information in the evaluation of progressive dementias. Although the CT scan is not capable of providing definitive diagnosis of Alzheimer's disease, it does exhibit utility in the ruling out of tumors, strokes, and hydrocephalus--which may be responsible for an inaccurate diagnosis of dementia or Alzheimer's disease. CT studies are not capable of illustrating the pathology which occurs in the temporoparietal cortex (24). While MRI and CT provide accurate information on cortical atrophy and periventricular white matter changes, nuclear medicine studies demonstrate regional cerebral blood flow changes not evidenced by these structural studies (32).

Functional Imaging. Alzheimer's disease is a focal illness in that it primarily attacks very specific regions of the brain. This disease tends to exhibit posterior hemisphere abnormalities, and studies reflect this pathology with a corresponding change in brain function (28,33). This fact is important, in that non-Alzheimer's dementia, frontal lobe dementia, and progressive supranuclear palsy show selective anterior abnormalities in SPECT studies as opposed to the posterior deficiencies exhibited in Alzheimer's disease (21,34,35). Specifically, Alzheimer's disease attacks the hippocampus and the neocortex (24). Hippocampal damage manifests itself by alteration in memory

functions. The neocortical damage usually manifests itself as the inability or change of a patient's ability to perform visual spatial skills, to perform certain language skill tasks, and to calculate and manipulate new information (33,36).

Functional imaging with modalities such as SPECT and PET enable the clinician to see focal hypometabolisms and perfusion deficits which, when coupled with the case history and physical exam, will lead to greatly improved diagnostic capabilities (33). PET studies done by Miller at UCLA have shown expected patterns in cerebral glucose metabolism. Namely, there is marked hypometabolism in the temporoparietal cortex and normal metabolism in the areas spared by the disease, principally the visual cortex and motor sensory strip (24). In patients with Alzheimer's, PET imaging has shown a significant decrease in glucose metabolism in the frontal, temporal, parietal, sensory-motor and striatal regions (37). In advanced cases, PET shows a reduction in metabolism that is uniformly dispersed throughout the cortex, sparing only the above-mentioned primary visual and sensory-motor cortices. This corresponds well with the neuropsychological findings in these patients (27).

Due to the high expense and limited availability of PET scanning, there has been an increased interest in the use of SPECT to assess regional blood flow. Studies utilizing I-123 labeled iofetamine have been performed to determine the diagnostic accuracy of this radiopharmaceutical in the assessment of Alzheimer's disease as compared with normal healthy patients. Results have been promising, yielding a sensitivity and specificity of 88% and 87%, respectively (30). Studies with this radiotracer, as with the PET studies, indicate whole-brain functional activity is reduced in Alzheimer's when compared to age-matched healthy control subjects, and that the temporoparietal and occipital regions were the most functionally impaired (30,38). Other research groups have been able to achieve similar results using SPECT and Tc-99m exametazime (38-43). This research also has been successful at illustrating a reduction in uptake in the posterior hemisphere of Alzheimer's-positive patients. Selective anterior deficits in other dementia types have illustrated the potential value of SPECT in the differential diagnosis of primary cerebral atrophies (29,34).

SPECT studies are rapidly becoming important in the diagnostic evaluation of patients showing memory and cognitive abnormalities (30). There are several clinical studies which indicate a high degree of accuracy in the assessment of patients with Alzheimer's in comparison with both normal subjects and patients with multi-infarct dementias (30,38). For severe cases

of Alzheimer's, the sensitivity of SPECT is very high, and in patients with mild impairment, sensitivity approaches 80% (30).

Experts state, "The predominant finding of bilateral posterior temporal and parietal perfusion defects in these patients is highly predictive of Alzheimer's disease (28)." The reduced radiotracer uptake may be due to several factors, such as, a reduced regional cerebral blood flow, decreased thickness of cortical tissue in the affected neocortex, and a reduced number of neurons in the affected areas. The combined effect of decreased cerebral blood flow and atrophy increase the diagnostic sensitivity of functional imaging modalities (28,39-47).

Depression

Disease Overview. Major depression is a common illness, with an annual incidence of 0.4-2.7 per 1000 people experiencing clinical depression. Close to seven percent of the population will experience a major depressive episode in their lifetime. The most significant risk factors for depression are genetic loading and progressing age. Depression usually presents as a mood disorder, but also may have other components associated with it, such as psychomotor disturbances and cognitive impairment, so called pseudodementia. This latter presentation can lead to misdiagnosis as primary degenerative dementia (48).

Major depression may also be referred to as a *unipolar* disorder, in that the patient experiences only depressive episodes without any episodes of mania. The depressive episodes are characterized by dysphoria, loss of interest in usually pleasurable activities, feelings of guilt, and psychomotor retardation or agitation. The major affective disorders may be further classified by whether the patient has a history of a manic episode. The manic patient may display groundless or excessive states of euphoria, hyperactivity, and aggression. The presence of current or past manic episodes justifies the diagnosis of a *bipolar* disorder. The patient may oscillate between periods of euphoria, dysphoria, and normal mood levels (46,77).

Researchers speculate that depression and its subsets are due to a functional disturbance in one or more of the cerebral monoamine pathways (13,48). Cell bodies of the monoamine systems are, in general, localized to the brainstem and send out protuberances to the subcortical and cortical structures. Whether the disturbance is linked to specific structures or whether it is more globally distributed has not been determined, although the limbic system has been frequently implicated (48-52).

As previously cited, physiological imaging has been shown to have certain clinical utility in diagnosing

dementia. However, SPECT and PET currently cannot be used in the primary diagnosis of depression. Further investigations are required to establish imaging differences between different subtypes of depression. Whether imaging modalities contain diagnostic or prognostic significance is the focus of ongoing research (5,13). There have been several studies over the last ten years which have discovered variations in metabolism or cerebral perfusion in depressed patients compared with controls (8,13,45). There are promising patterns in glucose metabolism and blood flow which are becoming apparent as more studies are completed. Thus, SPECT and PET studies do hold great promise in the future assessment of depressive illness.

PET Imaging. PET studies have shown regional decreases in glucose metabolism in both bipolar and unipolar depression (48,53,54). Whole brain hypometabolism is evidenced in bipolar patients, whereas subsets of unipolar patients show a more specific left frontal hypometabolism (54). Reductions in glucose metabolism in the left dorsal anterolateral prefrontal cortex have been consistently found by several researchers in patients with unipolar depression (48,54,55). The left to right relative asymmetry of the prefrontal cortex found in depressed patients has shown normalization of activity upon pharmacotherapy and electroconvulsive therapy (ECT), and correlates well with clinical improvement (48,54).

PET, when combined with statistical parametric mapping, has been utilized to study regional blood flow in depressed patients. The research identified dissociations between focal abnormalities in cerebral function due to mood disorders and related cognitive impairment. The depressed group as a whole showed decreased regional cerebral blood flow (rCBF) in the left anterior cingulate and the left dorsolateral prefrontal cortex. The patients that exhibited cognitive impairment showed additional significant decreases in regional blood flow in the left medial frontal gyrus and an increased rCBF in the cerebellar vermis (48). This is significant, in that it indicates an anatomical dissociation between the rCBF in the depressed state and depression-related cognitive impairment. Thus, PET has the potential to identify and differentiate between these two subtypes of depression.

SPECT Imaging. SPECT studies have paralleled many of the results found in PET. Detailed comparisons of depressed patients and controls show decreased perfusion in the anterior cingulate, temporal and frontal cortices, and in the caudate nuclei and thalami of men only (50,58). Unipolar major depressive patients, when imaged with Tc-99m exametazime, show a lower whole brain blood flow and reduced regional flow to the frontal, temporal, and parietal

lobes (51,56). Right inferior flow deficits are not uncommon in unipolar depression. The flow deficit in the right frontal lobe has been shown to be a result of circumferential hypoperfusion (8,57). This type of image is also found in bipolar disease, although it is not as common (8,13) (see Fig 3, Center Spread).

Bipolar depressives show higher flow values than normal in the left parietal and temporal lobes. Patients with rapidly cycling bipolar disorder have been shown to have dramatically increased activity in the right temporal lobe during periods of depression. This asymmetry was noted to normalize during periods of euthymia and after pharmacotherapy (36). Thus, current research has important applications in leading to a possible method of differential diagnosis between bipolar and unipolar disorders.

Some researchers are investigating the hypothesis that there is a "mood system," such as the prefrontal and limbic areas, which may constitute an anatomical network that may be functionally abnormal in patients exhibiting major depressive disorder (8,48). Major depression is associated with findings of functional changes in the left anterior cingulate and the left dorsolateral prefrontal cortex (48).

While not currently diagnostic for depression, PET and SPECT studies hold promise for assessing regional brain function in patients with depressive illness. Current research is investigating the usefulness of SPECT to differentiate depression with pseudodementia from primary dementia with secondary depression. SPECT is also being used to attempt differentiation of treatment resistant patients from those who respond well to pharmacotherapy (8,36) (see Figs 4a and 4b, Center Spread). Research along these lines may lead to a major role for SPECT in patient diagnosis, prognosis and treatment.

Obsessive-Compulsive Disorder.

Disease Overview. Obsessive compulsive disorder (OCD) is a classic psychoneurosis, which frequently has a secondary component of depression. This disorder is estimated to affect some five million Americans. Obsessive-compulsive disorder is generally considered as an anxiety disorder, and includes a family of psychological problems such as general anxiety, phobias, and repetitive, compulsive behaviors. **Obsessions** are repetitive and intrusive thoughts or impulses that are unwanted and distressing to the patient. The obsessions arise involuntarily despite attempts by the patient to suppress or ignore them. The most frequent topics of obsessions include violence, doubts about having performed routine tasks properly, and fear of contamination. The **compulsive** component of OCD is comprised of repetitive

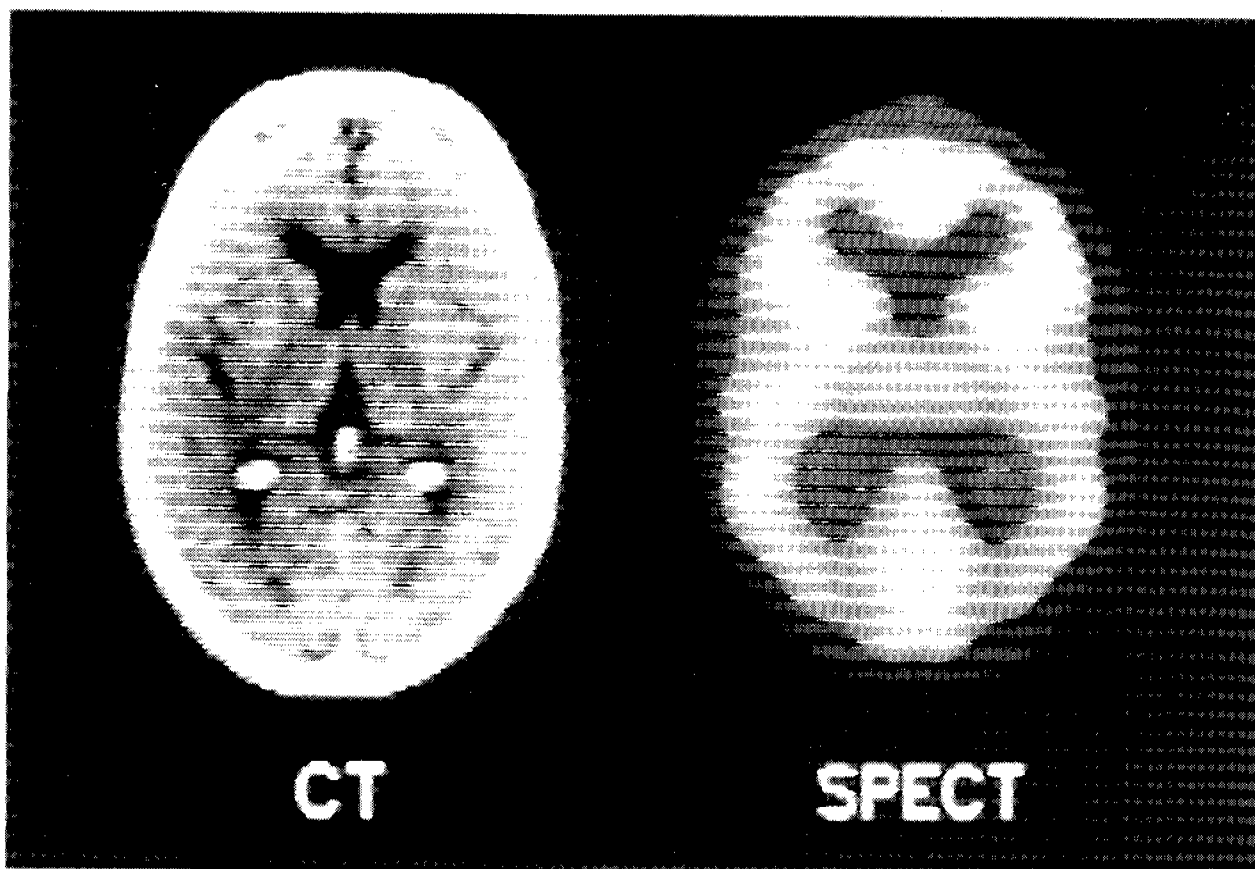


Figure 1. A normal *computed tomography* (CT) study (left) and a normal *single-photon emission computed tomography* (SPECT) study following the administration of the radiopharmaceutical technetium-99m exametazime (right). [courtesy of Dr. R.A. O'Connell (1)]

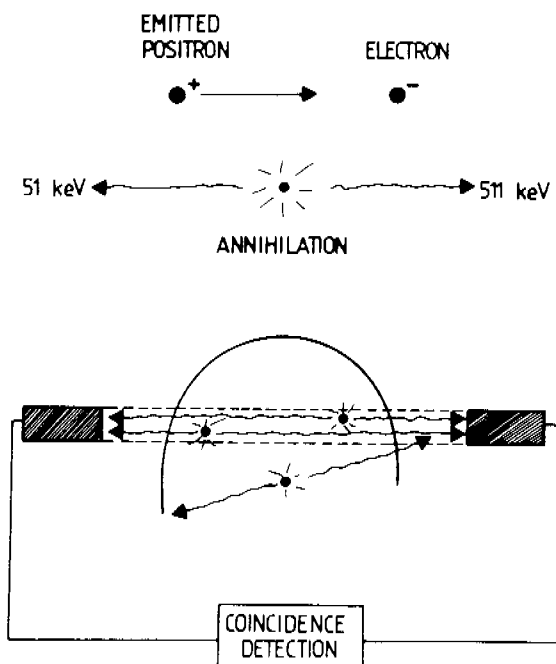


Figure 2. A schematic illustration of the detection of paired photons which have arisen from a positron-electron annihilation reaction. The coincidence counting records only those events that occur within the plane of tissue situated between the two detectors. [Reprinted with permission from Powell MP, Gibbs JM. Brain: positron emission tomography--¹³³Xenon blood flow. In: Davis ER, Thomas EG, (eds). *Nuclear Medicine: Applications to Surgery*. New York: Sheridan House. 1988:254-269.]

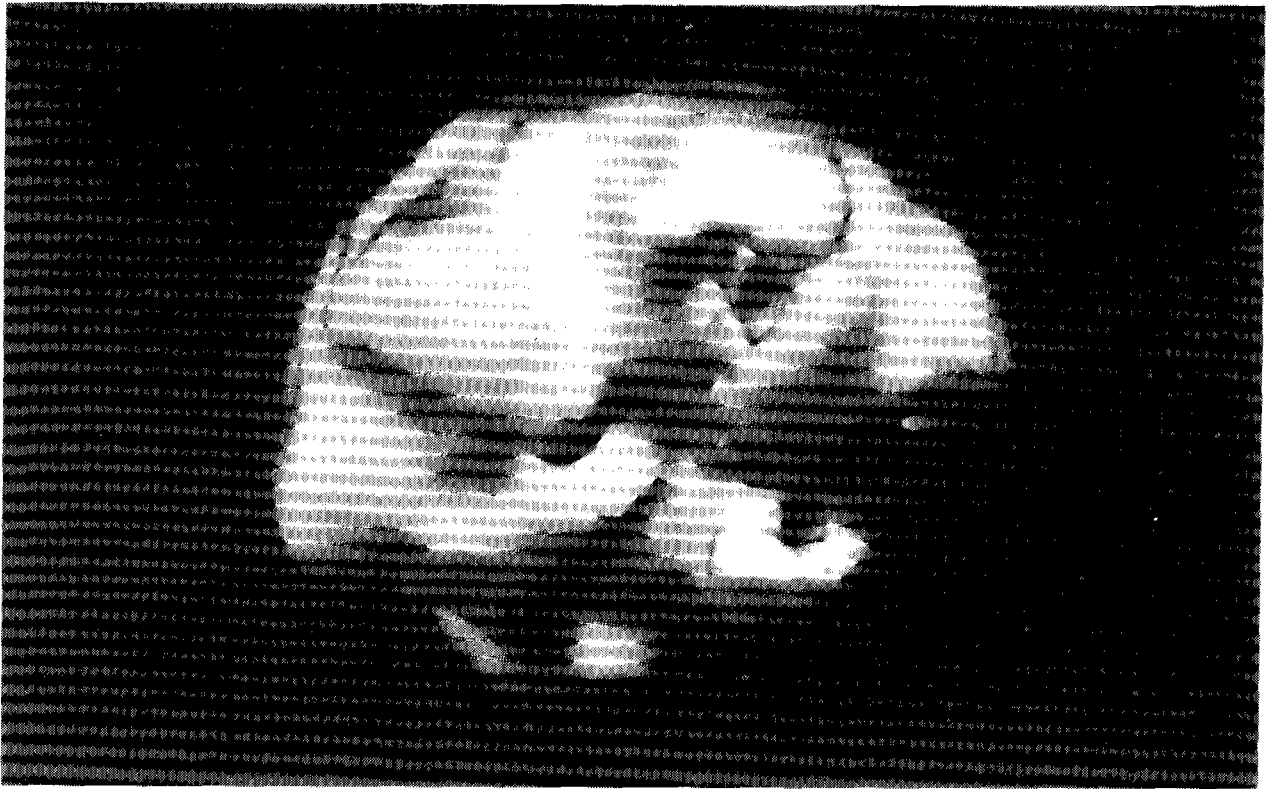


Figure 3. A three dimensional rCBF SPECT study in a patient with major depressive disorder (patient was medication-free). The study demonstrates right inferior frontal hypoperfusion and circumferential (medial worse than lateral) right temporal lobe hypoperfusion.

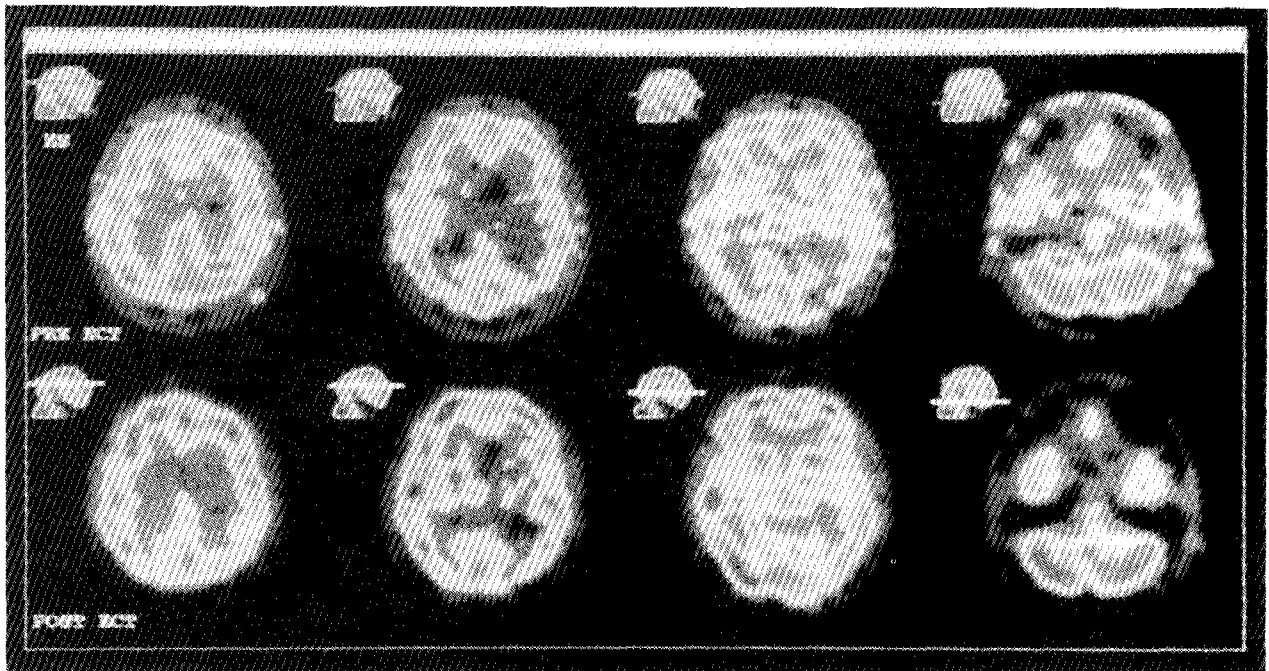


Figure 4a. Male patient with depression exhibiting significant clinical improvement upon treatment with electroconvulsive therapy as seen in this SPECT study obtained following the administration of technetium-99m exametazime (transaxial view). [courtesy of Dr. Lukasz Konopka, V. A. Hines hospital and Loyola University Medical School, Maywood, IL]

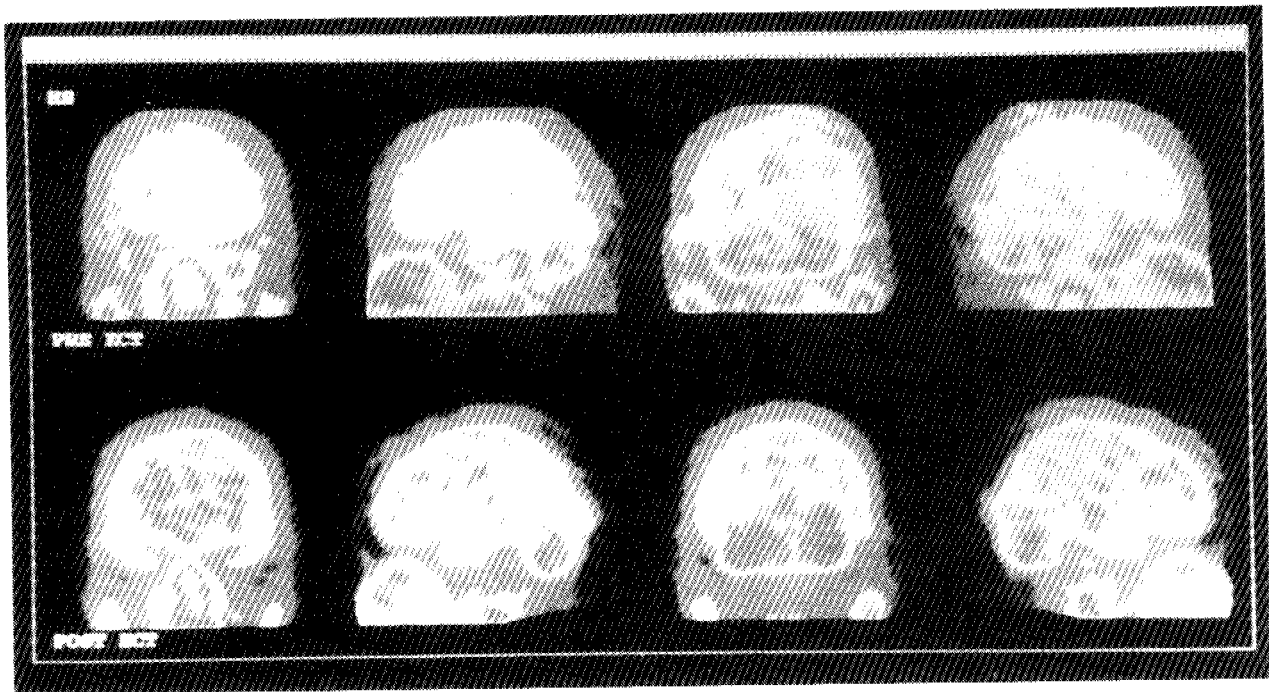


Figure 4b. Coronal view of same patient as in Figure 4a. [courtesy of Dr. Lukasz Konopka, V.A. Hines Hospital and Loyola University Medical School, Maywood, IL]

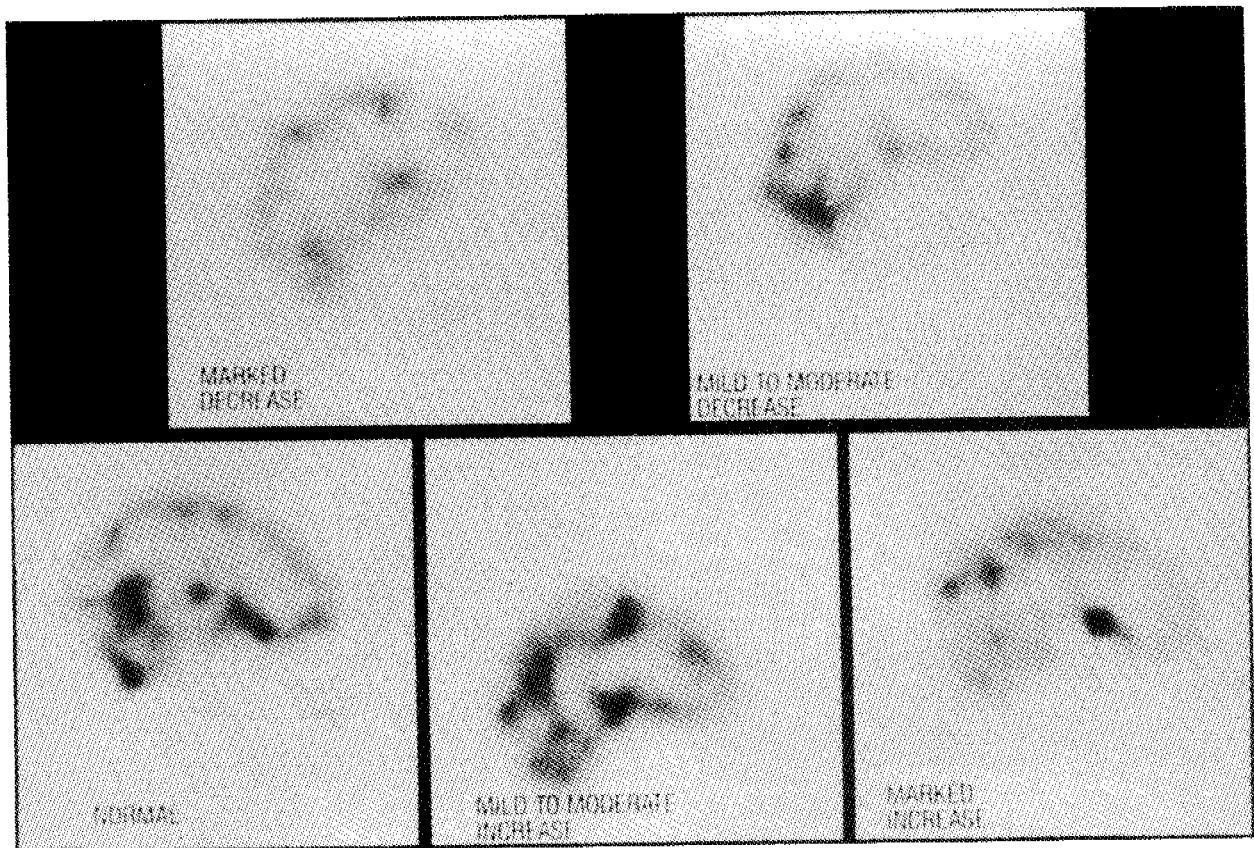


Figure 5. These SPECT studies show examples of increased and decreased perfusion in the frontal lobes of different medication-free patients. [courtesy of Dr. R.A. O'Connell (1)]

stereotypical acts which are performed reluctantly by the patient in an effort to alleviate intrusive thoughts. Some examples include hand-washing, touching, counting, and checking. Attempts are usually made by the individual to resist the ritual, as the frequency and duration of the repetitions make them inconvenient and even incapacitating. If the ritual is successfully prevented, obsessive-compulsive individuals become anxious (77).

The anatomic and biochemical basis of this disease has not been elucidated and is currently under intensive research. Many theories suggest a biological basis for the disorder (59-61). Current research suggests that OCD may involve dysfunction of serotonin neurotransmission and anatomical deficits in the orbital gyri (the left more than the right) and also in the caudate nuclei (59-62,77).

Recent imaging modalities (principally PET) have implicated brain malfunctions involving certain brain structures, principally the orbital prefrontal cortex and the striatum. The anterolateral prefrontal cortex, as previously discussed, has been implicated in the mediation of depression. This undoubtedly accounts for the imaging abnormalities identified in these areas during the investigation of OCD (60-62).

Results of research indicate that certain brain areas mediate the behaviors commonly expressed in obsessive compulsive patients (60,61). The orbital cortex is associated with the manifestation of anxiety, with impulse control, and conscientious attention to hygiene. Evidence also indicates that this region of the brain is involved in behavioral inhibition and extinction and perseverative behaviors. Abnormalities of orbital cortex function account for compulsive behaviors found in OCD patients (61).

The striatum is also thought to be involved in perseverative behavior. The caudate nucleus is a part of the striatum which receives projections from the inferior prefrontal cortex. This region of the striatum is associated with adventitious movement, and the resulting motor activities are mediated through the basal ganglia. Deficiencies in function in the caudate, along with the orbital areas, also produce similar perseverative difficulties in animal studies. This may account for the difficulty of OCD patients in ceasing their repetitive, compulsive behaviors. Pathology which is distributed throughout the striatum results in OCD symptoms, such as simple tics (lesions in the putamen), simple obsessive disorders (ventral medial part of the caudate), or complex thought disturbances (the more dorsal areas of the striatum). The compulsions that an OCD patient manifests arise in an effort to eliminate troublesome thoughts. These compulsions are mediated through motor activity via the cortex (61,62).

PET Imaging. PET with F-18 fluorodeoxyglucose is currently the most commonly employed imaging procedure being used to investigate OCD. Imaging yields elevations of relative glucose metabolism in frontal areas such as the orbital and anterior cingulate gyri, the basal ganglia, and the frontal orbital cortex (63). Reductions in radiotracer uptake have been seen in certain parietal regions. As previously noted, the heads of the caudate nuclei have been implicated. Interestingly, as with depression, glucose metabolism tends to normalize after pharmacotherapy (60,64-66).

SPECT Imaging. SPECT studies have yielded similar results (64,66). The striatum and the prefrontal cortex both utilize serotonin as a neurotransmitter. This correlates with the success OCD patients experience during treatment with serotonin uptake blockers such as fluoxetine (Prozac®, Dista).

In the future, PET imaging, along with receptor-specific ligands, could be used to investigate receptor level dysfunctions. Since the cortex-striatum integration is complex and involves many different transmitters, serotonin may not be the primary effector (61). I-123 iomazenil, a radioiodinated version of a benzodiazapine antagonist, allows SPECT evaluation of benzodiazepine receptors (10). The dopamine D₂ receptor can be evaluated with radiolabeled iodobenzamide (IBZM), a close analog of Raclopride (67-69). Yohimbine, when administered with Tc-99m exametazime, can be used to evaluate the alpha-2 vascular receptor by antagonizing it (69). Other receptor-based SPECT agents are currently under development and promise insight into the neuropharmacology of OCD and other disease states (64).

The use of SPECT or PET imaging, in OCD, currently has several obstacles which need to be overcome before physiological imaging with these modalities can become a routine clinical practice. This is due to the subtlety of the disease state process which requires further investigation. The consistent abnormalities, however, in the anterior cingulate gyrus, basal ganglia, and orbital-frontal cortex do indicate a high potential for application of nuclear medicine techniques in the evaluation of OCD (15). Further investigations into this disease state will help to elucidate the differences between this disorder and the affective disorders. The future holds promise as there is new and progressive research occurring in this area.

Schizophrenia

Disease Overview. Schizophrenia is not a single disorder but is a heterogeneous group of mental disorders, that result in severe and prolonged mental disturbance. Schizophrenia includes a wide gamut of severely disordered behavior. The clinical presentation invariably shows thought disturbances, hallucinations,

and delusions. The patient may also exhibit aberrant behavior and deterioration in the general level of functioning. In the United States, hospitalization due to schizophrenia occurs with a frequency of 1 in 100 persons and an estimated two million new cases of schizophrenia occur yearly throughout the world (77).

Schizophrenic symptomatology may be precipitated by social and psychological circumstances. Currently, there is evidence to suggest that regardless of the precipitating event, schizophrenia has an organic base. Evidence from twin studies indicate a genetic component to the disease. Investigations done with MRI and CT scanning show minor abnormalities in the brains of people with schizophrenia, primarily a size increase in the frontal and temporal horns of the cerebral ventricles. SPECT and PET studies are also effective in the investigation of the neurobiology of this serious illness (64).

The frontal lobes, basal ganglia, and temporal lobes have all been implicated in the pathology of schizophrenia as an organic disease. Evidence from brain imaging, postmortem studies, receptor studies, and psychopharmacologic studies support these suppositions. The frontal lobes are the sites for executive function and abstract thinking. Abnormalities in the function of this section of the brain coincide with the integrative and evaluative deficits encountered in schizophrenic patients. The basal ganglia are dopamine-rich, which accounts for the success of pharmacologic treatment with neuroleptic drugs that block dopamine receptors. The left temporal lobe is crucial in linguistic function. The disordered speech patterns and asymmetries in cerebral function implicate this particular region of the brain. Assessment of these specific regions of the brain can now be made via physiological imaging (64,69).

PET Imaging. The frontal lobes, as previously stated, are frequently the focus in schizophrenic physiological studies (Fig 5, see Center Spread). PET studies have addressed this area because decreased perfusion of the frontal lobes is theoretically expected due to the loss of function associated with the prefrontal cortex that is exhibited by these patients. Decreased perfusion in this area has been confirmed by many studies using a variety of imaging techniques (64,70,71). "Hypofrontality" has been reported by investigators using the Xe-133 two dimensional nontomographic blood flow method as well as SPECT and PET techniques (72-74).

SPECT Imaging. SPECT imaging of CBF using Xe-133 demonstrates hypofrontality in the left lobe and is found especially in patients of the paranoid type (72). A decrease in rCBF does not necessarily correlate with a decrease in glucose metabolism as evidenced by the negative "hypofrontality" findings of

several laboratories. However, the majority of PET and rCBF studies utilizing F18 FDG agree on the findings of low function in the frontal regions of patients with schizophrenia. SPECT studies with I-123 iofetamine have corroborated the findings of many PET studies (72,75,76).

The hypofrontality found in schizophrenia is not only something that is reported from imaging studies in patients. It is predicted on theoretical basis, as the frontal lobe controls attention, motivation, and organizational behaviors--and these behaviors are found deficient in patients with schizophrenia. Hypofrontality may be readily demonstrated via the use of a cognitive task utilized to stimulate the frontal cortex (72).

The basal ganglia and their specific role in basal ganglia-thalamus-cortex loops have also been implicated in schizophrenia. Dopamine and glutamate imbalance is proposed as the primary mechanism. The thalamus' role in the loop correlates with the inability of schizophrenia patients to filter incoming sensory stimuli and the resulting perceptual difficulties they experience. Autopsy studies reveal changes in receptor density and the effects noted with the use of neuroleptics are consistent with changes in the metabolic rate of the caudate and putamen (69,71).

In general, the data on perfusion or metabolism abnormalities of the basal ganglia in these patients are conflicting. Some of the reports indicate reduced metabolism in the basal ganglia of schizophrenic patients. However, other studies report normal basal ganglia and still others suggest enhanced perfusion (64,71). The bulk of the information indicates that enhanced metabolism or perfusion in the basal ganglia is, in fact, due to neuroleptic medication effects (64,73).

The left temporal lobe is the third region of interest in the evaluation of schizophrenia. Although wide methodologies have been used, most studies show lower metabolic rates in the left temporal lobe (71). Temporal lobe abnormalities are still inconclusive and require more research data before actual clinical correlations can be drawn.

The clinical assessment of schizophrenia with SPECT and PET has a number of potential applications. Nuclear medicine findings, such as that of hypofrontality, will allow psychiatrists and the nuclear medicine community to identify applications for these imaging technologies. For example, assessment of hypofrontality may be used to predict the success of treatment with neuroleptics. It may also be used to predict proper dosage and drug regimens. The perfusion hypofrontality observed with SPECT and PET imaging (especially when performed during psychological tasks to stress the prefrontal cortex) are rapidly approaching the stage where findings are consistent enough to warrant attempts at clinical application (64).

CONCLUSION

The unique information obtained from both PET and SPECT studies promise an exciting new addition to the psychiatric field. Functional imaging allows physicians to use diagnostic capabilities in more clinically relevant ways. These modalities have also provided an insight into a more detailed understanding of the intricate relationships between brain structure, function, and various psychiatric disease states. The development of PET has increased current understanding of the actual physiological functioning of the human brain. As with all new technologies, the application of dynamic imaging modalities such as PET, require the development of less expensive and less complicated technology (2). As a result, research with SPECT has been intense. SPECT is currently more accessible and much less costly than PET. Better radiopharmaceuticals and improved imaging technology have already improved the resolution of SPECT, drawing its capabilities closer to that of PET. Further advances in SPECT will allow regular clinical application in diagnosis of psychiatric illness.

The unique information provided by functional imaging modalities can certainly help to minimize costs incurred by prolonged diagnostic evaluations, incorrect diagnoses, and therapeutic mismanagement. These procedures also promise applications in the tailoring of treatment regimens on the basis of neurochemical and brain function characteristics of the patient (67). In conclusion, as the use of nuclear medicine in psychiatry progresses, more potential clinical applications will continue to evolve.

References

1. O'Connell RA. SPECT brain imaging in schizophrenia. In: St. Vincent's Hospital, sponsor. *A Seminar from the American Psychiatric Association's 43rd Institute on Hospital and Community Psychiatry*; 1991 Oct 19: Los Angeles.
2. Shuckit MA. An introduction and overview to clinical applications of neuroSPECT in psychiatry. *J Clin Psych* 1992;53(Suppl):3-6.
3. Saha GP. *Fundamentals of Nuclear Pharmacy*. New York: Springer-Verlag; 1986:197-201.
4. Spence AP, Mason EB. *Human Anatomy and Physiology*. Menlo Pk, CA: Benjamin/Cummings Co; 1983:309-335.
5. Burt AM. *Textbook of Neuroanatomy*. Philadelphia: W.B. Saunders Company. 1993:117-499.
6. Carpenter MB. *Core Text of Neuroanatomy*. 3rd ed. Baltimore: Williams and Wilkins. 1985:13-14.
7. Barr ML, Kiernan JA. *The Human Nervous System*. 5th ed. New York: JB Lippencott. 1988:373-375.
8. Devous MD. Comparison of SPECT applications in neurology and psychiatry. *J Clin Psych* 1992; 53(Suppl):13-19.
9. Powell MP, Gibbs JM. Brain: positron emission tomography--¹³³Xenon blood flow. In: Davies ER, Thomas EG, editors. *Nuclear Medicine: Applications to Surgery*. New York: Sheridan House. 1988:254-269.
10. Innis RB. Neuroreceptor imaging with SPECT. *J Clin Psych* 1992;53(Suppl):29-34.
11. Sokoloff L. Basic principles in imaging of regional cerebral metabolic rates. In: Sokoloff L. editor. *Brain Imaging and Function*. New York: Raven Press. 1985:21-48.
12. Raichle ME, Mintun MA, Herscovitch P. Positron emission tomography with 15 oxygen radiopharmaceuticals. In: Sokoloff L. editor. *Brain Imaging and Function*. New York: Raven Press. 1985:51-59.
13. Phelps ME, Mazziotta JC, Baxter L, Schwartz, Gerner R. Study design in the investigation of mood disorders with PET. In: Sokoloff L. editor. *Brain Imaging and Function*. New York: Raven Press. 1985:227-243.
14. Lassen NA. Measurement of regional cerebral blood flow in humans with single-photon-emitting radioisotopes. In: Sokoloff L. editor. *Brain Imaging and Function*. New York: Raven Press. 1985:9-19.
15. Van Heertum RL. Brain SPECT Imaging and Psychiatry. *J Clin Psych* 1992;53(Suppl):7-12.
16. Kimura K, Hashikawa K, Etani H, Uehara A, Kozuka T, Moriaki H, et al. A new apparatus for brain imaging: four-head rotating gamma camera single-photon emission computed tomograph. *J Nucl Med* 1990;31:603-607.
17. Holman BL, Carvalho PA, Zimmerman RE, Johnson KA, Tumeh SS, Smith AP, et al. Brain perfusion SPECT using an annular single crystal camera: initial clinical experience. *J Nucl Med* 1990;31:1456-1461.

18. Van Heertum RL: Advances in nuclear medicine brain imaging. In: St. Vincent's Hospital, sponsor. *A Seminar from the American Psychiatric Association's 43rd Institute on Hospital and Community Psychiatry*: 1991 Oct 19: Los Angeles.
19. Nakano S, Kinoshita K, Jinnouchi S, Hoshi H, Watanabe K. Critical cerebral blood flow thresholds studied by SPECT using xenon-133 and iodine-123 iodoamphetamine. *J Nucl Med* 1989;30:337-340.
20. Greenberg JH, Kushner M, Rango M, Alavi A, Reivich M. Validation studies of iodine-123-iodoamphetamine as a cerebral blood flow tracer using emission tomography. *J Nucl Med* 1990;31:1364-1367.
21. Smith FW, Besson JA, Gemmell HG, Sharp PF. The use of technetium-99m-HMPAO in the assessment of patients with dementia and other neuropsychiatric conditions. *J Cereb Blood Flow Metab* 1988;8(Suppl 1):116-122.
22. Woods SW. SPECT brain imaging in anxiety and drug abuse disorders. In: St. Vincent's Hospital CE Program. *A Seminar from the American Psychiatric Association's 43rd Institute on Hospital and Community Psychiatry*: 1991 Oct 19: Los Angeles.
23. Hopkins A. *Clinical Neurology: A Modern Approach*. New York: Oxford University Press. 1993: 167-444.
24. Miller BL. SPECT brain imaging in Alzheimer's disease. In: St. Vincent's Hospital CE Program. *A Seminar from the American Psychiatric Association's 43rd Institute on Hospital and Community Psychiatry*: 1991 Oct 19: Los Angeles.
25. Miller BL, Cummings JL, Villanueva-Meyer J, Boone K, Mehlinger CM, Lesser IM, et al. Frontal Lobe Degeneration: Clinical, neuropsychological, and SPECT characteristics. *Neurology* 1991;41:1374-1382.
26. Morris JH. The Nervous System. In: Robbins AL, Kumar V, editors. *Basic Pathology*. Philadelphia: W.B. Sanders Company. 1987:723-754.
27. Postiglione A, Lassen NA, Holman BL. Cerebral blood flow in patients with dementia of Alzheimer's type. *Aging-- Clinical and Experimental Research*. 1993;5(No 1):19-26.
28. Holman BL, Devous Sr, MD. Functional brain SPECT: the emergence of a powerful clinical method. *J Nucl Med* 1992;33:1888-99.
29. Holman BL, Johnson KA, Gerada B, Carvalho PA, Satlin A. The scintigraphic appearance of Alzheimer's disease: a prospective study using Technetium-99 -HMPAO SPECT. *J Nucl Med* 1992;33:181-5.
30. Johnson KA, Holman BL, Rosen TJ, Nagel JS, English RJ, Growden JH. Iofetamine I-123 single photon emission computed tomography is accurate in the diagnosis of Alzheimer's disease. *Arch Intern Med* 1990;150:752-756.
31. Dierckx RA, Vandewoude M, Saerens J, Hartoko T, Marien P, Capiu I, et al. Sensitivity and specificity of Tc(m)-99-HMPAO single-headed SPECT in dementia. *Nucl Med Comm* 1993;14:792-7.
32. Cohen MB, Graham LS, Lake R, Metter EJ, Fitten J, Mangala KK, et al. Diagnosis of Alzheimer's disease and multiple infarct dementia by tomographic imaging of iodine-123 IMP. *J Nucl Med* 1986;27:769-774
33. Grunwald F, Horn R, Rieker O, Klemm E, Menzel C, Moller HJ, et al. HMPAO-SPECT in dementia of the Alzheimer type and major depression with memory impairment [abstract]. *Nuklearmedizin* 1993;32:128-33.
34. Neary D, Snowden JS, Shields RA, Burjan AW, Northen B, MacDermott N, et al. Single photon emission tomography using 99m Tc-HMPAO in the investigation of dementia. *J Neurol Neurosurg Psychiatry* 1987;50:1101-9.
35. Holman BL, Johnson KA, Gerada B, Carvalho PA, Satlin A. The Scintigraphic appearance of Alzheimer's disease: a prospective study using technetium-99m-HMPAO SPECT. *J Nucl Med* 1992;33:181-5.
36. Mozely PD. SPECT brain imaging in patients with depression. In: St. Vincent's Hospital CE Program. *A Seminar from the American Psychiatric Association's 43rd Institute on Hospital and Community Psychiatry*: 1991 Oct 19: Los Angeles.
37. Goto I, Taniwaki T, Hosokawa S, Otsuka M, Ichiya Y, Ichimiya A. Positron emission tomographic (PET) studies in dementia. *J Neurol Sci* 1993;114:1-6.
38. Sharp P, Gemmell H, Cherryman G, Besson J, Crawford J, Smith F. Application of iodine-123-labeled isopropylamphetamine imaging to the study of dementia. *J Nucl Med* 1986;27:761-768.

39. Launes J, Sulkava R, Erkinjuntti T, et al. Tc-99m HMPAO SPECT in suspected dementia. *Nucl Med Comm* 1991;12:757-765.
40. O'Brien JT, Eagger S, Syed GM, Sahakian BJ, Levy R. A study of regional cerebral blood flow and cognitive performance in Alzheimer's disease. *J Neurol Neurosurg Psychiatry* 1992;55:1182-87.
41. Liu HC, Liu RS, Lin KN, Wang SJ, Fuh JL, Yeh SH, et al. Single photon emission computed tomography using Tc-99m-HMPAO in Alzheimer's disease. *Nucl Med Comm* 1992;13:535-541.
42. Robert P, Migneco O, Darcort J, Ricq O, Aubin V, Bonhomme P, et al. Correlation between Tc-99m-HMPAO brain uptake and severity of dementia in Alzheimer's disease--assessment using automated technique. *Dementia* 1992;3:15+.
43. McEwan AJ, Jackson FI, Catz Z, Schmidt RP, Hooper HR, Matthews JJ. Tc-99m HMPAO to demonstrate diffuse cortical necrosis in vivo. *Clin Nucl Med* 1991;16:167-9.
44. Habert MO, Spampinato U, Mas JL, Piketty ML, Bourdel MC, Derecondo J, et al. A comparative technetium-99m hexamethylpropylene amine oxine SPECT in different types dementia. *Eur J Nucl Med* 1991;18:3-11.
45. Van Heertum RL, O'Connell RA. Functional brain imaging in the evaluation of psychiatric illness. *Semin Nucl Med* 1991;21:24-39.
46. Holman BL, Johnson Ka, et al. The scintigraphic appearance of Alzheimer's disease: a prospective study using technetium-99m-HMPAO SPECT. *J Nucl Med* 1992;33:182-185.
47. Jaoust WJ, Reed BR, Seab JP, Budinger TF. Alzheimer's Disease: Old age onset and single photon emission computed tomographic patterns of regional cerebral blood flow. *Arch Neurol* 1990;47:628-33.
48. Bench CJ, Friston KJ, Brown RG, Scott LC, Frackowiak RS, Dolan RJ. The anatomy of melancholia--focal abnormalities of cerebral blood flow in major depression. *Psychol Med* 1992;22:606-15.
49. Wu JC, Gillin JC, Buchsbaum MS, Hershey T, Johnson C, Bunney WE. Effect of sleep deprivation on brain metabolism of depressed patients. *Am J Psychiatry* 1992;149:538-542.
50. Wu JC, Buchsbaum MS, Johnson JC, Hershey TG, Wagner EA, Teng C, et al. Magnetic resonance and positron emission tomography imaging of the corpus callosum--size, shape, and metabolic rate in unipolar depression. *J Affective Disorders* 1993;28:15-25.
51. Bolwig TG. Regional cerebral blood flow in affective disorder [abstract]. *ACTA--Psychiatrica--Scandinavica* 1993;87(s 371):48-53.
52. Dolan RJ, Bench CJ, Brown RG, Scott LC, Friston KJ, Frackowiak RJ. Regional cerebral blood flow abnormalities in depressed patients with cognitive impairment. *J Neurol Neurosurg Psychiatry* 1992;55:768-773.
53. Baxter LR, Phelps ME, Mazziotta JC, Schwartz JM, Gerner RH, Selin CE, et al. Cerebral metabolic rates for glucose in mood disorders. Studies with positron emission tomography and fluorodeoxyglucose F18. *Arch Gen Psychiatry* 1985;42:441-447.
54. Martinot JL, Hardy P, Felin A, Huret JD, Mazoyer B, Attar-Levy D, et al. Left prefrontal glucose hypometabolism in the depressed state: a confirmation. *Am J Psychiatry* 1990;147:1313-1317.
55. Devous MD, Gullion CM, Granneman B, Rush AJ. Regional cerebral blood flow alterations in unipolar depression. *J Nucl Med*. 1991;32:951-952.
56. Maes M, Dierckx R, Meltzer HY, Ingels M, Schotte C, Vandewoude M, et al. Regional cerebral blood flow in unipolar depression measured with Tc-99m-HMPAO single photon emission computed tomography--negative findings. *Psychiatry Research Neuroimaging* 1993;50:77-88.
57. Mayberg HS, Jeffery PJ, Wagner HN, Simpson SG. Regional cerebral blood flow in patients with refractory unipolar depression measured with Tc-99m-HMPAO SPECT. *J Nucl Med* 1991;32:951.
58. Curran SM, Murray CM, Van Beck M, Dougall N, O'Carroll RE, Austin MP. A single photon emission computerised tomography study of regional brain function in elderly patients with major depression and with Alzheimer-type dementia. *Br J Psychiatry* 1993;163:155-165.
59. Foa EB, Wilson R, Barlow DH. *Stop Obsessing: How to Overcome Your Obsessions and Compulsions*. New York: Bantam Books. 1991: 3-26.

60. Baxter LR, Schwartz JM, Guze BH, Bergman K, Szuba MP. PET imaging in obsessive disorder with and without depression. *J Clin Psychiatry* 1990;51:61-68.
61. Baxter LR. Brain imaging as a tool in establishing a theory of brain pathology in obsessive compulsive disorder. *J Clin Psychiatry* 1990;51(Suppl):22-25.
62. Baxter LR. Brain imaging as a tool in establishing a theory of brain pathology in obsessive compulsive disorder. *J Clin Psychiatry* 1990;51(Suppl):22-25.
63. Baxter LR, Schwartz JM, Mazziotta JC, Phelps ME, Pahl JJ, Guze BH, et al. Cerebral glucose metabolic rates in nondepressed patients with obsessive-compulsive disorder. *Am J Psychiatry* 1988;145:1560-1563.
64. Woods SW. Regional cerebral blood flow imaging with SPECT in psychiatric disease: focus on schizophrenia, anxiety disorders, and substance abuse. *J Clin Psychiatry* 1992;53(Suppl):20-25.
65. Harris GJ, Camargo EE, Machlin SR, Hoehn-Saric R, Rivera-Luna J, Links JM, et al. SPECT imaging of regional cerebral blood flow in obsessive compulsive disorder. *J Nucl Med* 1990;31:750.
66. Goodman WK, McDougle CJ, Price LH, Riddle MA, Smith EO, Hoffer PB, et al. Spect imaging of obsessive-compulsive disorder with Tc-99m d,l-HMPAO. *J Nucl Med* 1990;31:750-751.
67. Volkow ND, Tancredi L. Current and future applications of SPECT in clinical psychiatry. *J Clin Psychiatry* 1992;53(Suppl):26-28.
68. Volkow ND. Overview of SPECT brain imaging in psychiatry. In: St. Vincent's Hospital, sponsor. *A Seminar from the American Psychiatric Association's 43rd Institute on Hospital and Community Psychiatry*: 1991 Oct 19: Los Angeles.
69. Buchsbaum MS. Frontal lobes, basal ganglia, temporal lobes--three sites for schizophrenia. *The Schizophrenia Bulletin* 1990;16:377-378.
70. Bajc M, Medved V, Basic M, Topuzovic N, Babic D. Cerebral perfusion inhomogeneities in schizophrenia demonstrated with single photon emission computed tomography and Tc99m-hexamethylpropylamineoxim. *Acta Psychiatry Scandinavia* 1989;80:427-433.
71. Buchsbaum M. The frontal basal ganglia, and temporal lobes as sites for schizophrenia. *The Schizophrenia Bulletin* 1990;16:379-387.
72. Cohen MB, Lake RR, Graham LS, King MA, Kling AS, Fitten J, et al. Quantitative iodine-123 IMP imaging of brain perfusion in schizophrenia. *J Nucl Med* 1989;30:1616-1620.
73. Berman KF, Weinberger DR. Functional localization in the brain in Schizophrenia. In: Tasman A, Goldfinger SM, eds. *Review of Psychiatry*. Vol 10. Washington DC: American Psychiatric Press; 1991:59-73.
74. Devous MD. Imaging brain function by single-photon emission computer tomography. In: Andreasen NC. editor. *Brain Imaging Applications in Psychiatry*. Washington, DC: American Psychiatric Press; 1989:147-234.
75. Devous MD, Raese JD, Herman JH, et al. SPECT determination of regional cerebral blood flow in schizophrenic patients at rest and during a mental task [abstract]. *J Nucl Med* 1986;27:734.
76. Jones T. The application of PET. In: Ell PJ, Holman BL. *Computed Emission Tomography*. New York: Oxford Press. 1982.
77. Goldman HH. *General Psychiatry*. Norwalk, CT: Appleton and Lange. 1988:241-477.
78. Phan T, Ling M, Wasnich R. *Practical Nuclear Pharmacy*. Hawaii: Banyan Press. 1987:80-146.
79. Buell U, Krappel W, Schmiedek P, et al. I-123 amphetamine vs. Xe-133 SPECT. A comparative study in patients with unilateral cerebrovascular disease. *J Nucl Med* 1985;26:P25.

QUESTIONS

1. Nuclear medicine brain imaging
 - a. shows function (physiology), as opposed to structure (anatomy).
 - b. shows structure (anatomy), as opposed to function (physiology).
 - c. shows both anatomy and function.
 - d. does not show either function or anatomy.

2. The basal ganglia, structures which are implicated in the manifestation of obsessive-compulsive disorder
 - a. integrate sensory information and coordinate the resulting motor responses.
 - b. connect the cerebellum to the brain stem and the cerebrum.
 - c. are aggregates of neuronal cell bodies which are involved in somatic (inhibitory) motor functions.
 - d. are passageways composed of nerve fiber tracts extending between the spinal cord and the higher brain regions.

3. During the decay of a positron-emitting nuclide, the nucleus will release
 - a. a particle with a single excess negative charge.
 - b. a particle with a single positive charge.
 - c. two positively charged particles traveling in 180 degree opposite trajectories.
 - d. both a and c

4. PET and SPECT brain imaging techniques are similar in that they both
 - a. utilize radioactive deoxyglucose in scanning procedures.
 - b. utilize radionuclides which emit only one photon per disintegration.
 - c. can be used in routine clinical practice.
 - d. can produce tomographic images.

5. Advantages of PET imaging include:
 - a. PET is capable of attaining high image resolution.
 - b. PET is capable of evaluating important metabolic processes of the brain (i.e., glucose metabolism).
 - c. PET imaging is readily accessible and inexpensive.
 - d. a and b

6. SPECT imaging can be used to show
 - a. neuroreceptor density
 - b. regional cerebral blood flow
 - c. oxygen consumption
 - d. a and b

7. Advantages of SPECT brain imaging over that of PET include which of the following?
 - a. SPECT is capable of attaining consistently higher image resolution.
 - b. SPECT utilizes methods and equipment currently found in many hospital nuclear medicine departments.
 - c. SPECT imaging is less expensive and less technically cumbersome.
 - d. b and c

8. Which of the following statements are **true** of SPECT brain imaging?
 - a. The SPECT approach utilizes accelerator-produced radionuclides which necessitate the presence of an on-site cyclotron.
 - b. The majority of SPECT radiopharmaceuticals measure benzodiazapine receptor density.
 - c. The majority of SPECT radiopharmaceuticals are brain perfusion or cerebral blood flow agents.
 - d. a and c

9. In patients with symptoms of Alzheimer's disease, SPECT brain imaging can help
 - a. increase diagnostic accuracy especially when combined with patient history and structural evaluations.
 - b. clearly illustrate the marked sulcal widening common in the brain atrophy found in this disease.
 - c. assist in the differential diagnosis of brain tumor and Alzheimer's disease.
 - d. a and c

10. In patients with Alzheimer's disease, SPECT brain studies
- demonstrate decreased blood flow in the temporoparietal cortex.
 - demonstrate increase cerebral blood flow to the temporoparietal cortex.
 - demonstrate marked deoxyglucose glypometabolism in the temporo-parietal cortex.
 - demonstrate insular atrophy common in this disease.
11. When performing PET brain imaging on a patient with Alzheimer's disease, one might expect to see which of the following?
- normal glucose metabolism in the visual cortex
 - normal glucose metabolism in the motor sensory strip
 - decreased glucose metabolism in the parietal region
 - all of the above
12. In patients with symptoms of depression, SPECT scanning can
- provide a definitive diagnosis.
 - augment treatment of depression.
 - assist in the differentiation of unipolar depression and bipolar depression.
 - show regional decreases in left frontal glucose metabolism.
13. PET studies performed on depressed patients have shown which of the following?
- whole brain hypometabolism in bipolar depression patients
 - left frontal hypometabolism in unipolar depression patients
 - normalization of profrontal cortex asymmetries in depressed patients, upon pharmaceutical and electroconvulsive therapies
 - all of the above
14. Which of the following statements pertaining to imaging in depression can be regarded as **true**?
- The prefrontal and limbic areas are thought by researchers to constitute a "mood system" which may be functionally abnormal in depressed patients.
 - The temporal, parietal and motor-sensory areas are thought by researchers to constitute a "mood system" which may be functionally abnormal in depressed patients.
 - Both PET and SPECT studies have shown decreased perfusion in the anterior cingulate and frontal cortices of depressed patients.
 - a and c
15. Examples of PET brain imaging agents include the following:
- $(^{11}\text{C})\text{d-glucose}$
 - $(^{18}\text{F})\text{2-deoxy-2 flouro-d-glucose}$
 - $(^{192}\text{Ir})\text{-deoxyglucose}$
 - a and b
16. Which of the following common behaviors, expressed in obsessive-compulsive patients, correctly corresponds with its associated brain region?
- orbital cortex--compulsions and anxiety
 - putamen--simple tics
 - dorsal striatum complex thought disturbances
 - all of the above

17. Which of the following statements is **true** regarding obsessive-compulsive (OCD) behavior?
- Obsessive-compulsive patients frequently experience anxiety, compulsions, and hallucinations.
 - Positron Emission Tomography with L(¹¹C)-aspartate is the most commonly employed imaging procedure to investigate OCD.
 - a and b
 - none of the above
18. Schizophrenic patients exhibit which of the following abnormalities?
- size increases in the frontal and temporal horns of the cerebral ventricles as seen by MRI and CT studies
 - decreased frontal lobe blood flow demonstrated by Xenon-133 and SPECT
 - cortical atrophy and sulcal widening demonstrated by Tc-99m labeled exametazime and SPECT
 - a and b
19. Which of the following have been implicated in the pathology of schizophrenia?
- frontal lobes
 - basal ganglia
 - temporal lobes
 - all of the above
20. Which of the following is a commonly-employed SPECT brain imaging agent for psychiatric applications?
- Tc-99m labeled exametazime
 - Tc-99m labeled DTPA
 - Tc-99m labeled deoxyglucose
 - none of the above
21. "Hypofrontality" is a common finding in patients with
- depression
 - Alzheimer's disease
 - obsessive-compulsive disorder
 - Schizophrenia
22. Enhanced metabolism or perfusion in the basal ganglia of schizophrenic patients upon PET or SPECT imaging is most likely due to
- exceptionally large basal ganglia found in schizophrenic patients
 - neuroleptic medication administration
 - back scatter from surrounding brain structures
 - idiopathic inflammatory lesions
23. SPECT brain scanning may be useful in clinical psychiatry for:
- differential diagnosis
 - monitoring treatment regimens
 - measuring receptor densities
 - all of the above
24. Imaging of rCBF with I-123 iofetamine is probably best performed at what time period post injection?
- within the first 20 minutes
 - after 1 hour
 - after 3 hours
 - after 6 hours
25. What imaging modality and corresponding radiolabeled compound are currently the most frequently utilized in the assessment of obsessive-compulsive disorder?
- positron emission tomography and ¹⁸F-fluoro-deoxyglucose
 - positron emission tomography and 2-(¹¹C)-deoxy-D-glucose
 - single photon emission computed tomography and Tc-99m labeled exametazime
 - single photon emission computed tomography and I-123 iofetamine

