



The University of New Mexico ♦ Health Sciences Center
COLLEGE OF PHARMACY



:::VOLUME 14, LESSON 4:::

Imaging Technology Changing Cancer Therapy

Continuing Education for Nuclear Pharmacists
and
Nuclear Medicine Professionals

By

Dee H. Wu, Ph.D.
Associate Professor, Section Chief
Technology Application Development and
Translational Research Department of Radiological Sciences
OUHSC



The University of New Mexico Health Sciences Center College of Pharmacy is accredited by the Accreditation Council for Pharmacy Education as a provider of continuing pharmaceutical education. Program No. 039-000-08-004-H04-P and 039-000-08-004-H04-T. 1.0 Contact Hours or .1 CEUs.

-- Intentionally left blank --

Imaging Technology Changing Cancer Therapy

By
Dee H. Wu, Ph.D.

Editor, CENP

Jeffrey Norenberg, MS, PharmD, BCNP, FASHP, FAPhA
UNM College of Pharmacy

Editorial Board

Sam Augustine, R.P, PharmD, FAPhA
Stephen Dragotakes, RPh, BCNP, FAPhA
Richard Kowalsky, PharmD, BCNP, FAPhA
Neil Petry, RPh, MS, BCNP, FAPhA
James Ponto, MS, RPh, BCNP, FAPhA
Tim Quinton, PharmD, BCNP, FAPhA
S. Duann Vanderslice, RPh, BCNP, FAPhA

Director, CENP

Kristina Wittstrom, RPh, BCNP
UNM College of Pharmacy

Administrator, CE & Web Publisher

Christina Muñoz, B.S.
UNM College of Pharmacy

While the advice and information in this publication are believed to be true and accurate at the time of press, the author(s), editors, or the publisher cannot accept any legal responsibility for any errors or omissions that may be made. The publisher makes no warranty, expressed or implied, with respect to the material contained herein.

Copyright 2008
University of New Mexico Health Sciences Center
Pharmacy Continuing Education
Albuquerque, New Mexico

IMAGING TECHNOLOGY CHANGING CANCER THERAPY

STATEMENT OF LEARNING OBJECTIVES:

1. What are goals and objectives of 3D cross sectional imaging (MRI, CT) for oncology, what are they doing now and where are they going?
2. What is the role of Imaging for Radiation Treatment planning, current capabilities and future potentials?
3. What is the role of Contrast Agents in Oncology?
4. What is the role of Image Fusion Techniques in Oncology?

COURSE OUTLINE

LEVELS OF IMAGING TARGETS FOR CANCER	7
STRUCTURAL IMAGING	9
FUNCTIONAL IMAGING (CT, MRI AND PET).....	9
MOLECULAR IMAGING (NUCLEAR AS THE PRIME MOLECULAR IMAGING MODALITY).....	10
IMAGE FUSION.....	11
“MULTIMODALITIES” – TRYING TO GET THE BEST OF MULTIPLE 'LEVELS' OF IMAGING	12
FUTURE DIRECTIONS	13
REFERENCES	14
ASSESSMENT QUESTIONS	15
APPENDIX	16
APHA LIVE PRESENTATION SLIDES	16

-- Intentionally left blank --

Presented at 2008 Annual APhA Meeting

IMAGING TECHNOLOGY CHANGING CANCER THERAPY

by

Dee H. Wu, Ph.D.
Associate Professor, Section Chief
Technology Application Development and
Translational Research Department of Radiological Sciences
OUHSC

Over the last decade, with the advent of improved imaging technologies, we gained the ability to see tremendous new things. These developments are of great value to physicians, who seek ever-improved understanding of disease processes. Most medical subspecialties rely on some imaging to help them to differentiate among various possible sequelae of various diseases. For example the ubiquitous x-ray machine is used at minimal energies (kilovolts) to get contrast in an image; radiation therapy applications may call for much higher energies (megavolts) to destroy cancerous tissue. We rely on high quality instrumentation (often guided by power computer processes and inherent physics of the device) to create snapshots of the disease. Critical to understanding clinical imaging of cancer is to recognize which phenomena is the physiological target \The degree to what physiological processes are imaged we describe next as the ‘levels of imaging’ targets.

LEVELS OF IMAGING TARGETS FOR CANCER

To understand what imaging modalities are capable of, we must discuss what the intended levels of observation are being evaluated. We will discuss 5 levels: structural, functional, molecular, extracellular, and intercellular. The easiest level to understand is the structural. This level includes anatomical parts of the body such as bone, brain, and lung. It is common for many modalities, such as computed tomography (CT), magnetic resonance imaging (MRI), and ultrasound (US) to be used to evaluate structural changes in our bodies that can be due to disease. The next level is ‘functional’ and refers to observing images over a time period. It is important to note that we often use contrast agents to enhance differences in tissue behavior. By viewing the introduction of contrast agents dynamically, each spatial point location is interrogated over time to gain an understanding of the underlying mechanisms of vascularity and permeability of the tissue. Tumors often exhibit avid contrast uptake

due to the hypervascularity and increased leakiness of the tumor environment. Multiple time points on a 3D volume can be processed and displayed in two ways. First, they may be collapsed across time into a composite set of values based on a formula so that each spatial point is represented by a parametric value that reflects a characteristic of the uptake process. The other way is to observe a movie of the changes over time. The later is much more inconvenient to use because often we must delineate changes based on spatial values only. Some methods do not require contrast agents, such as functional MRI (fMRI), which refers to identifying regions of the brain that responds to the presence of neurocognitive stimuli. Some drug companies are beginning to test psychotropic medicine influences by fMRI and Positron Emission Tomography (PET). The latter we will discuss in a later section. Other pharmaceutical manufacturers evaluate dynamic contrast enhancement (DCE) imaging to better understand the impact of their drugs on tumor suppression. The current frontier for imaging scientists exists at the molecular level. This includes the immune system, receptors, and hormone and steroid effects, which all interact on the molecular level.

While this molecular imaging field may be described as currently developing and employing emerging technology, it appears to promise to be vital. First of all, most disease processes originate at the molecular level. For example the onset of hormonal growth signals can induce changes in vascularity. A dynamic contrast enhancement study can be used to study the vascularity changes in a tumor. These types of studies are often referred to as ‘perfusion’ imaging. Viewing images over time implies analysis at the ‘functional’ level. All function is guided and planned through protein systems that are imprinted by genetic information from (DNA/RNA) mechanisms. Alterations in protein levels are made at the molecular level. The flow of functional information to genes is considered “Central Dogma” by biologists and is fundamental to our study of cell physiology. Also when sufficient damage is made to anatomy by function or by molecular disruption, we observe using ‘structural’ imaging. Observing at the molecular level becomes more appealing because we may be able to intervene before functional or structural damage has occurred. The molecular level has been the most challenging to utilize and much emerging research is being conducted at this time.

The cellular level can be broken down into imaging extracellular space and intracellular space. It is perhaps of greatest desirability to image within the cell since this is where the RNA is transcribed from blue-prints made by DNA within the nucleus. There are mechanisms that can produce contrast at the extracellular level. Contrast agents that leak out of the porous tumor vessels produce observable signal. Intracellular imaging modalities are currently unrealistic for most practical work.

Cancer progresses from lowest levels (cellular and molecular), followed by functional changes (as visualized through the vasculature), to finally a structural damage level. Often visualization of the disease process earliest in the states of cancer is critical to being able to 'cure' cancer, which provides great current motivation to have 'molecular and functional' information available to the physicians.

Structural Imaging

Cross-sectional methods are important to give not only anatomical details but exact spatial location of disease markers. Computed tomography (CT) is the primary methodology outside the CNS. Hounsfield Units (HU) can be used to determine the location of fat, calcium, water and blood. Hounsfield unit (HU) scale is a linear transformation of the attenuation coefficient (μ) measurement at each spatial location (based on evaluated value for air and water). The linear transformation to Hounsfield units is $HU = (\mu_{\text{Substance}} - \mu_{\text{H2O}}) / (\mu_{\text{H2O}} - \mu_{\text{Air}})$. The linear attenuation coefficient (μ) describes the extent to which the intensity of x-ray reduction as it passes through a specific material. The specific values for different tissues permit CT to be very suitable for image segmentation. Image segmentation is the process of taking an image and identifying different tissues based on the values at different points. The ability to make density estimates of tissues based on HU, and its accuracy in spatial position, has made it a modality of choice for simulation in radiation therapy (RT) since it is easy to apply image segmentation and the geometric precision available in CT over most other modalities. Simulation (using CT) in RT is utilized in the planning of how the radiation will be delivered to the patient, based on the location and types of tissues the therapeutic beams will traverse.

In some cases, MRI seems to have some advantages over CT in the brain and spine due to the fact that these structures are encased in bone, which attenuates signal on CT. MRI has much greater sensitivity to the edema that is present in tumors and produces significantly greater contrast in the brain and the spine. While displaying some tumors better, one complication of MRI is that there can be spatial distortion caused by the variability of patient head shapes. Both MRI and CT are good fundamental possibilities for performing image fusion.

FUNCTIONAL IMAGING (CT, MRI and PET)

The use of rapid dynamic scans when a contrast agent study has been performed may be helpful to characterize the early rate of increase of the tumor or washout phase of the tumor. A rapid wash-in that rapidly washes out has been suggested to be indicative of a large degree of vascularity and thus is

suspected to have a greater degree of malignancy than a lesion that slowly enhances and continues to enhance. Following the passage of a tracer (contrast agent) is available for most modalities. However, it takes great expertise to interpret and draw functional data from scans. Functional imaging capabilities are available clinically but have not often reached their full potential. Recently, Breast MRI with contrast agents to evaluate function are now applied clinically.

MOLECULAR IMAGING (Nuclear as The Prime Molecular Imaging Modality)

Nuclear medicine is enormously important in molecular imaging. Despite much lower resolution compared to CT (~ .5-1 mm resolution) and MRI (~ 1.5 - 2mm resolution), nuclear imaging methods produce powerful contrast based on molecular characterization of tissues. Positron Emission Tomography (PET) displays lymph areas that are avid uptake of FDG conjugated contrast agents. Such areas have high glucose metabolism usage which the greedy tumors need for rapid cell development. The PET machine despite its low number of possible radiopharmaceutical agent plays a big role in the detection and staging of cancer. Often what is seen on images can be integrated into the evaluation of the tumor size, presence of lymph node involvement and spread. These criteria are used in the TNM system which comes from the American Joint Committee on Cancer (AJCC): T describes the size and location of invasion of the primary tumor, N describes the lymph node involvement, and M describes the level of metastasis in the body.

SPECT can be used in specific cases for some cancers but has even poorer resolution and signal to noise (SNR) than PET. We are often concerned with the ability to discern lesions within the presence of electronic noise of the instrumentation. As imagers attempt to seek smaller resolution, the amount of available signal becomes reduced thus making the image more grainy and difficult to detect objects within confidence. A formal definition of SNR can vary slightly but perhaps can be thought of as the ratio of average signal (electronic units) that is used to produce the image over the signal (electronic units) that is present due to the instrumentation accuracy. To learn more you may ask a subspecialty nuclear medicine pharmacist colleague. Nuclear pharmacists are vital for efficient and accurate assembly of the agents used in nuclear medicine. They are a resource and knowledge base with respect to radiopharmaceuticals and commonly interact with the healthcare professionals responsible for use of radiopharmaceuticals in nuclear medicine.

	PET	SPECT
Resolution	Higher (typical best ~3-4 mm)	Lower (typical best ~6-7 mm)
Signal to Noise Ratio	Higher	Lower
Contrast	Dependent on application Much higher for Glucose Metabolism	Dependent on application
Primary Compounds	FDG for most cancers	Iodine for Thyroid Cancer Phosphonates –Bone scan Sestamibi - Heart HMPAO; ECD - Brain MIBG –Tumor Tc-99M labeled leukocytes – white cells

Table 1: A comparison between PET and SPECT modalities in clinical usage for cancer. It is important to note this is a dynamic table which changes over time.

MRI also has the capability to perform molecular imaging using spectroscopy techniques.

Spectroscopy refers to the measurement of 'spectra' which in the case of proton MR is the amount of frequency difference between the resonance frequency of water with the chemical of interest. This resonance difference is known as the chemical shift phenomenon. Different types of molecular compounds present in cancer such as MRS are a powerful, non-invasive, non-destructive tool to study chemical compositions and metabolic processes. Proton MRS detects signal from protons from metabolites other than water such as creatine (energetics marker), choline (cell wall breakdown), N-acetylaspartate (neuronal integrity), and Myo-inositol (estimates cell wall processes) and Lactic acid (anaerobic activity).

Image Fusion

We will now switch from simple discrete biological imaging modalities to methods which attempt to combine images from multiple target levels into a single composite image. At the most desirable level of automatic image fusion, the method can be extremely complex. The technique relies on image registration, image segmentation, and image scaling methods. Even with access to the above methods, image fusion requires a high level of expertise in technology applications. Fine adjustments in image

location may be required because molecular or functional information may spatially not be as accurate as structural images. This can be made by individuals on the care team to ensure consistency in localization of molecular/functional data with high resolution. In the ideal situation, this team would consist of radiation oncologists, dosimetrists, diagnostics radiologists, medical physicists, and nurses. However, it is not always possible to have all representative fields available for the study due to cost constraints. Most important is involvement by the physicians, as it is they who best understand disease processes and are the responsible party for patient care.

Once a final image fusion of two modalities has been made it is ready to be used by radiation oncologists for treatment planning. In some cases image fusion can show that the cancer has spread, which can further inform the treatment plan. Exact alignment of the primary structural images with a matched molecular/functional image will determine the tumor boundaries for final treatment.

“Multimodalities” – trying to get the best of multiple 'levels' of imaging.

We have previously described MRI and CT as structural methods, and PET and SPECT as two molecular imaging methodologies. There is great promise in combining modalities, as well. Recall the burden of automated image fusion/registration methods between different modalities. To apply a concrete example, try to imagine the position you lay in your bed just before you got up. Now imagine that some one asked you to go back and lie in the exact position to millimeter accuracy. Even with preplanning this would be very hard, and additionally people aren't stiff rods connected together but have parts that fluidly slide in position in unlimited directions. This hints at the dilemma of trying to integrate separate units of imaging. However, there has been a real convergence to create multimodality machines. Of great success was PET/CT. Now imagine performing the CT first and then PET (sequentially over a couple minutes) by sliding the patient through both units in the same session. If the patient can maintain position for a couple of minutes, they provide the opportunity to achieve better alignment and thus better image fusion. This has revolutionized medical imaging in this area; the use of most dedicated PET machines is being phased out in favor of PET/CT. CT has large potential for radiation exposure. However, for oncology purposes the combination of information from PET with CT can be critical.

SPECT/CT is also available and has a bright future. Recall SPECT has many more possible agents for targeting specific disease. This will likely replace some dedicated SPECT machines in the future and has some potential use in emergent situations.

FUTURE DIRECTIONS

MRI/PET is now on the future planning tables of all vendors. Most information concerning its design have not been disclosed since there are no human based scanners in the clinics currently. However, this combination could have the potential to be groundbreaking in its potential to do true simultaneous measurement by both machines (instead of sequential). MRI also has the capacity to image different inherent contrasts of 'water' shifts in the body. Additionally, MRI has a strong functional capacity, which lends it to useful techniques such as fMRI neurocognitive function and Dynamic Contrast Enhancement Imaging (DCE-MRI). There is thus potential for there to be the proliferation of MRI/PET scans to a level to the success as recently seen by CT/PET systems (especially at high end medical centers).

Aside from developing imaging modalities, great works are being put together by different medicinal chemists and pharmacologists. The same contrast agents that are used to detect vascularity changes or molecular changes can be tagged with antibodies, for example. These will stick to the tumor or disease of interest, and potentially produce even greater contrast. The use of macrocyclics (dendrimers) now enable packing large numbers of contrasts together which also has potential to drive the conspicuity of small tumors. Finally, a combination of sensing agents can be packed together for localized delivery of the agents. This would permit greater dosages because systemic complications have been reduced.

REFERENCES

1. Yuh WTC. An exciting and challenging role for the advanced contrast MR imaging. *JMRI* 1999;10(3):221-222.
2. Stark D, Bradley W. *Magnetic Resonance Imaging*. New York: Mosby, 1992.
3. Folkman J. Tumor angiogenesis: therapeutic implications. *N Engl J Med* 1971;285(21):1182-1186.
4. Alpert B, Johnson A, Lewis J, Raff M, Roberts K, Walter P. *Molecular Biology of the Cell*. New York: Garland Press, 2002.
5. Wu DH, Archer AG, Hast LJ. *Fundamentals of Achieving Functional and Anatomical Imaging with Breast MRI: Physical and Clinical Concepts to appear in Breast Imaging* New York: Society for Photo-Optical Instrumentation Engineers (SPIE) Press 2006
6. Pietrzyk U. Image Fusion. In: Oehr P, Biersack HJ, Coleman RE, eds. *PET and PET-CT in Oncology*. Berlin: Springer-Verlag, 2004: 10-20.
7. Beyer T, Townsend DW. *Dual-Modality PET/CT Acquisition Systems for Clinical Oncology*. Berlin: Springer-Verlag 2004.
8. Imam SK. Molecular nuclear imaging: the radiopharmaceuticals (review). *Cancer Biother Radiopharm* 2005;20(2):163-172.

ASSESSMENT QUESTIONS

1. Which modality has the highest spatial resolution
 - a. SPECT
 - b. MRI
 - c. CT
 - d. PET

2. Which modalities are used for purposes of radiation treatment planning
 - a. PET
 - b. CT
 - c. MRI
 - d. SPECT
 - e. All of the above

3. Which contrast agent below is **not** used for visualizing cancer?
 - a. FDG based (with PET)
 - b. NO₂-based agent (with SPECT)
 - c. Gd-based chelate (with MRI)
 - d. I-based (with CT)
 - e. All of the above are used in image fusion

4. Which of the below techniques are **not** used in image fusion:
 - a. Image registration
 - b. Image segmentation
 - c. Image remodeling
 - d. Image scaling
 - e. All above are used in image fusion

Imaging Technology Changing Cancer Therapy

Dee H. Wu, Ph.D.
Chief, Technology Applications and Translational Research



The University of Oklahoma
Health Sciences Center

Outlining Some Basic Challenges

Part 1: Levels of observing cancer (by imaging)

- a) anatomical
- b) functional*
- c) molecular

*Also interpretation for staging such as lymphography

Part 2: Rapid advances in radiation therapy

- a) Chemo-radiation
- b) planning via functional/molecular

Part 3: Hybrid modalities (primarily nuclear?)

- a) PET-CT / PET-SPECT
- b) PET-MRI (futures??)

** **Two way street- Clinical Imaging and Animal Preclinical Imaging**




The University of Oklahoma
Health Sciences Center

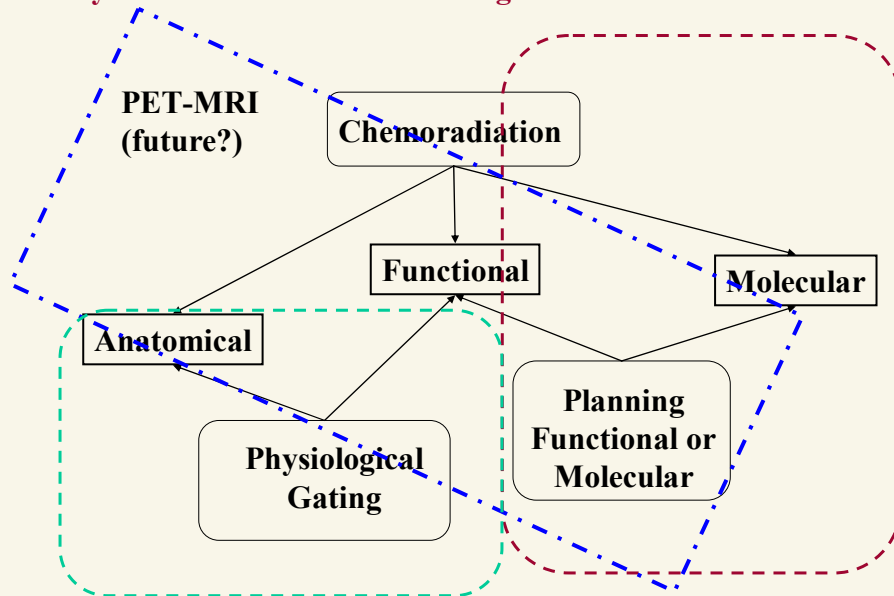
STATEMENT OF LEARNING OBJECTIVES:

Large Focus are the ‘levels’ of observation targets for cancer with imaging.

- What is the role of Contrast Agents in Oncology?
- What is the role of Image Fusion Techniques/Hybrid modalities in Oncology?



Birds Eye View: Some Basic Challenges



Part Ia: Levels of Imaging Targets (Anatomical)

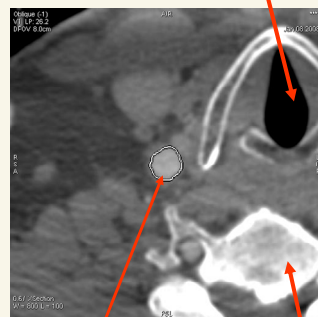
- 1) Type of lesion
- 2) Internal enhancement patterns
- 3) Shape of lesions
- 4) Margins of lesions
- 5) Associated findings

From Chapter 2: Wu, DH; Archer, AG; Hast, LJ et al; Fundamentals of Achieving Functional and Anatomical Imaging with Breast MRI: Physical and Clinical Concepts
Recent Advances in Mammography, Breast Imaging 2006 SPIE Press Suri, eds



The University of Oklahoma
Health Sciences Center

CT as an example of structural Information



Vessel

Bone

$$HU = \frac{\mu_{\text{Substance}} - \mu_{\text{H2O}}}{\mu_{\text{H2O}} - \mu_{\text{Air}}}$$

Hounsfield Unit (HU) scales
Value of linear attenuation
coefficient
To air and water. The attenuation
coefficient is the property of the
mater to permit the amount of x-
rays passing through that material



The University of Oklahoma
Health Sciences Center

Part Ib: Levels of Imaging Targets (Functional)

- Functional can provide ‘time-series’ observation by imaging (such as observing contrast uptake)
- Can it provide differential diagnosis (such as provide evidence of malignancy)?
- Discuss Angiogenesis (evaluate function)



The University of Oklahoma
Health Sciences Center

Examine Angiogenesis First Discussing Normal Vessels

- Vessel organization (patterns of capillaries, arteries and venules) is determined by the oxygen and metabolic needs of tissue.
- Endothelial vessels are supported by cells called pericytes.
- Blood flow is consistent in Normal Vessels



The University of Oklahoma
Health Sciences Center

Tumor Angiogenesis

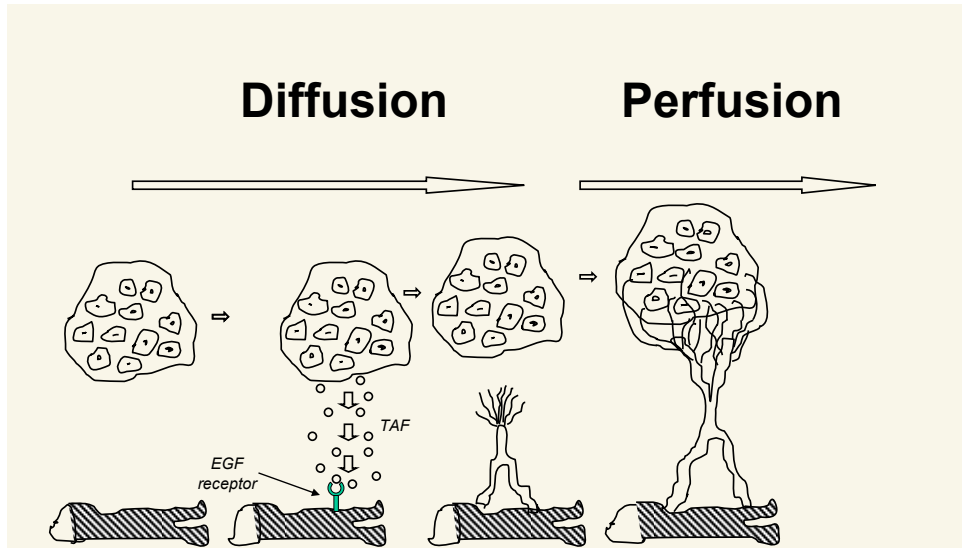
- Tumors utilize normal functions to develop their own blood supply.
- In 1971, Dr. Judah Folkman proposed that a tumor angiogenesis factor diffuses into the microenvironment and initiates the generation of tumor blood vessels.



Tumors require their own blood supply

- Provides nutrients for survival and growth.
- Viable cells within 100-200 mm of blood vessels.
- Areas of tumors that lack blood supply or have crushed vessels:
 - Become hypoxic (low oxygen) and
 - Necrotic (lytic cell death which releases toxic cell components, without apoptosis – programmed cell death).





From Chapter 2: Wu, DH; Archer, AG; Hast, LJ et al; Fundamentals of Achieving Functional and Anatomical Imaging with Breast MRI: Physical and Clinical Concepts
Recent Advances in Mammography, Breast Imaging 2006 SPIE Press Suri, eds. 2005

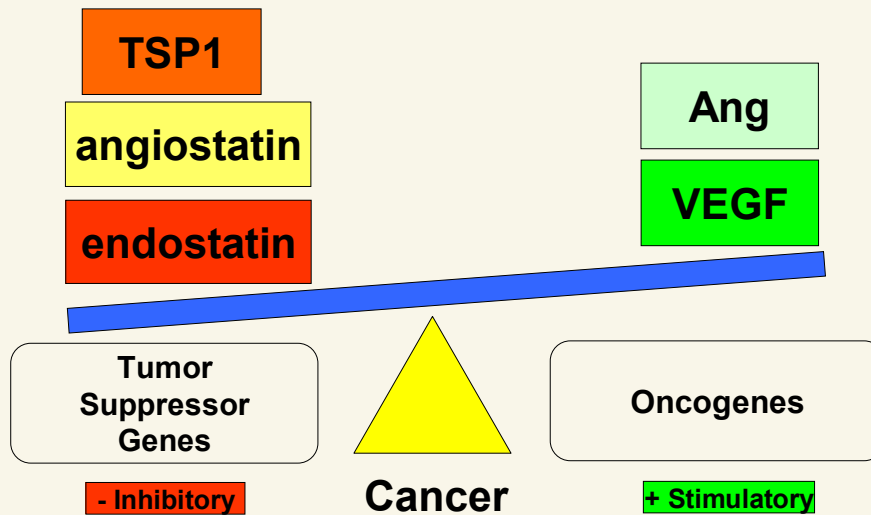


Vasculogenesis

- In the embryo:
 - Hemangioblast cells, differentiate into endothelial cells for the vessel lining and hematopoietic cells of the blood.
- In adults:
 - Circulating endothelial progenitor cells are believed to form endothelial channels called a primitive network.



Judith Folkman



The University of Oklahoma
Health Sciences Center

Angiogenic Switch

- During tumor development a disruption between pro- and anti-angiogenic molecules occurs.
 - Allows continued proliferation of tumor cells
 - Oncogene-driven production of growth factors by tumor cells
 - Changes in the tumor microenvironment
 - Recruitment of progenitor endothelial cells from bone marrow
 - Downregulation of natural inhibitors of angiogenesis



The University of Oklahoma
Health Sciences Center

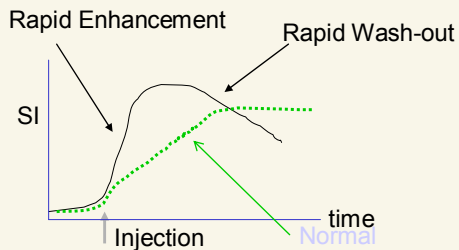
Tumor Vessels (Abnormal)

- Lack characteristic organizational patterns of capillaries, arteries and venules.
- Tortuous, dilated and irregular in shape.
- Can be dead-ended and leaky due to high VEGF levels and changes in perivascular cell numbers and associations.
- Tumor cells can be part of the vessels.
- Blood flow in tumors may be slow and intermittent.

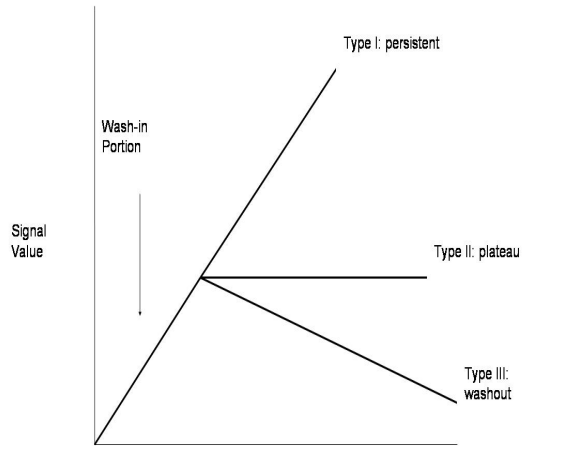


Uptake Characterization for Assessing Blood Flow (dynamic contrast enhancement imaging)

The use of rapid dynamic scans may be helpful to characterize the early rate of increase of the tumor or washout phase of the tumor. A rapid wash-in that rapidly washes out has been suggested to be indicative of a large degree of vascularity and thus is suspected to have a greater degree of malignancy than a lesion that slowly enhances and continues to enhance.



Later on we will talk about implication to the Clinic



Chapter 2: Wu, DH; Archer, AG; Hast, LJ et al; Fundamentals of Achieving Functional and Anatomical Imaging with Breast MRI: Physical and Clinical Concepts
Recent Advances in Mammography, Breast Imaging 2006 SPIE Press Suri, eds. 2005



The University of Oklahoma
Health Sciences Center

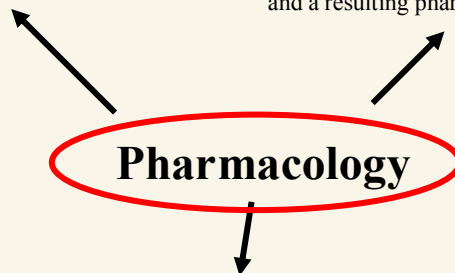
Goals of Functional Pharmacology

Pharmacokinetics (PK)

time course of drug concentrations resulting from a particular dosing regimen

Pharmacodynamics (PD):

relationship between drug concentrations and a resulting pharmacological effect



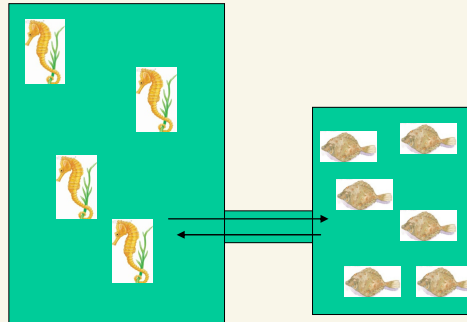
Pharmacotherapeutics (PT)

The study of the use of drugs



The University of Oklahoma
Health Sciences Center

Fish Tank Analogy (for Kinetics) Recall chemical equilibrium



Tank 1

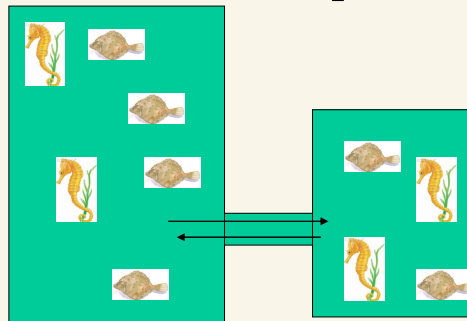
Tank 2

Initial conditions



The University of Oklahoma
Health Sciences Center

Fish Tank Analogy (for Kinetics) Recall chemical equilibrium



Tank 1

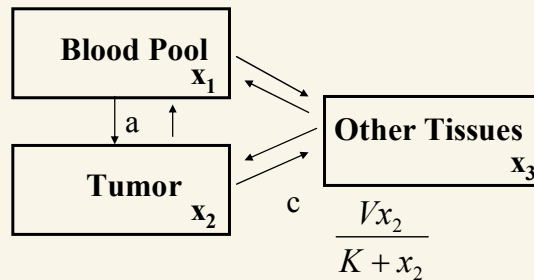
Tank 2

Final Conditions



The University of Oklahoma
Health Sciences Center

Pharmacokinetic Parameters



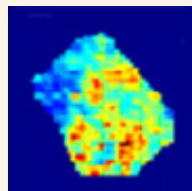
x_1, x_2, x_3 , represent amounts of the drug
Transfer between compartments
(Recall Equilibrium Constants from Chemistry?)



The University of Oklahoma
Health Sciences Center

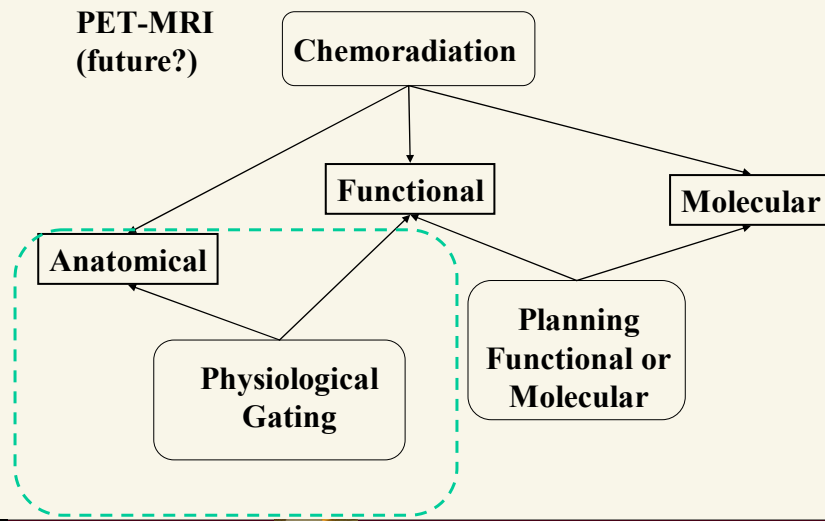
Example of Pharmacokinetic Based Image

To make compatible with pharmacokinetics
Parameters from images are constructed via
the same. (Hotter Colors have for example
larger k_{12} which reflect faster exchange
into the tumor)

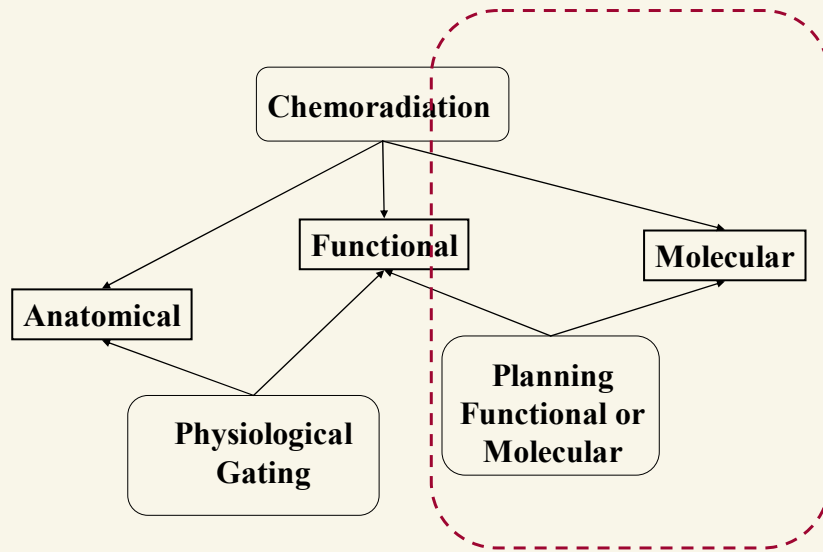


The University of Oklahoma
Health Sciences Center

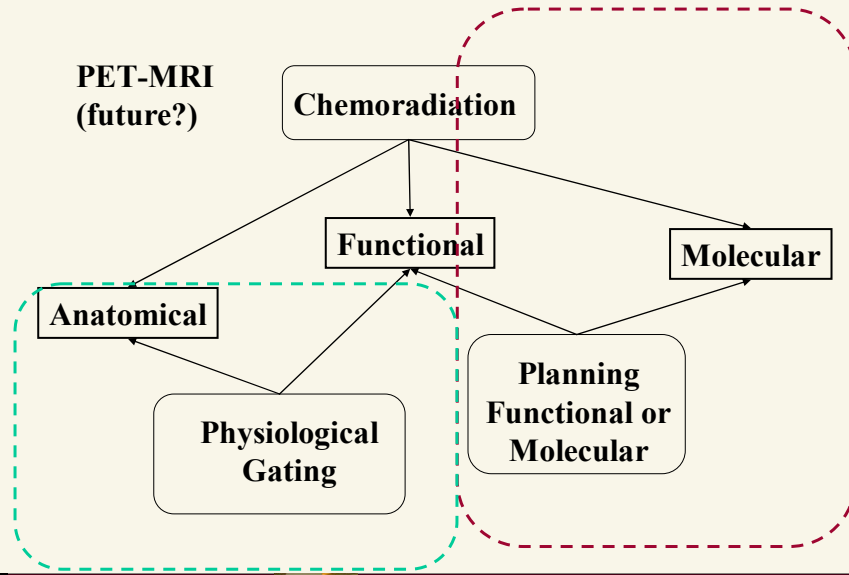
Birds Eye View: CT (that's most common)



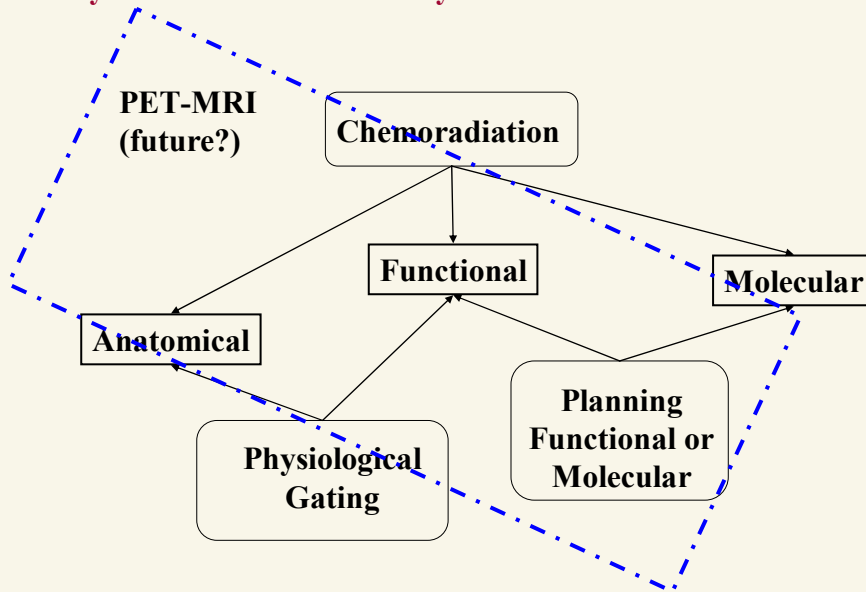
Birds Eye View: PET




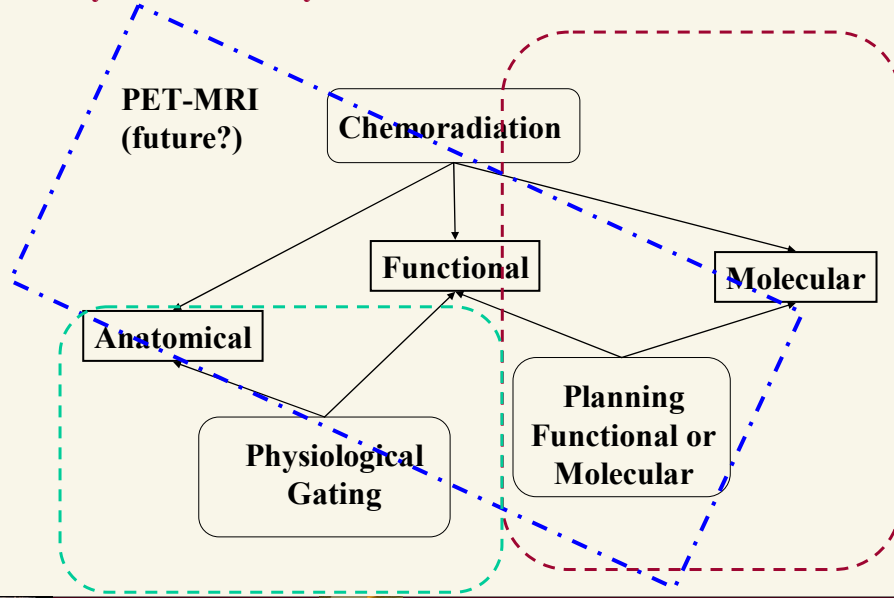
Birds Eye View: PET/CT



Birds Eye View: PET/MRI – maybe in the future???

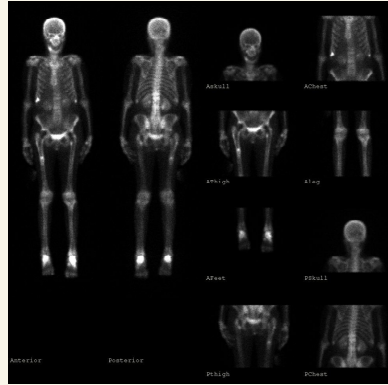
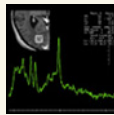
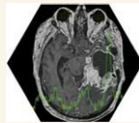
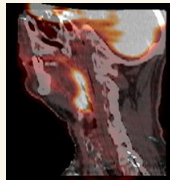
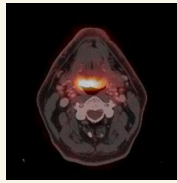


Birds Eye View: Ideally we have choices to have all?



The University of Oklahoma
Health Sciences Center

Part Ic: Levels of Imaging Targets (Molecular)




The University of Oklahoma
Health Sciences Center

Example 1: Cancer (high or low grade astrocytoma)

Improvements in neuroimaging permit the diagnosis of many low-grade astrocytomas that would not have been recognized previously. Low-grade astrocytomas are, by definition, **slow growing, and patients survive much longer** than those with high-grade gliomas. Proper **management involves recognition, treatment of symptoms (eg, seizures), and surgery, with or without adjunctive therapy.**

<http://www.emedicine.com/MED/topic2693.htm> Author: Tobey MacDonald, MD &
<http://www.emedicine.com/ped/topic154.htm> Author Jeffrey N Bruce, MD



The University of Oklahoma
Health Sciences Center

Impact Clinically (Decision based on Spectroscopy)

Instead of Increase in Radical Treatment, patient with a low grade astrocytoma was monitored for changes. This may give some improvement to Quality of Life for this patient.



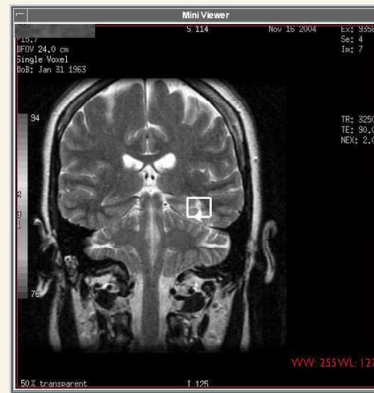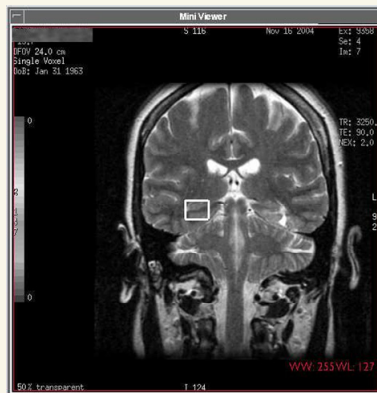The University of Oklahoma
Health Sciences Center

Tuberous sclerosis

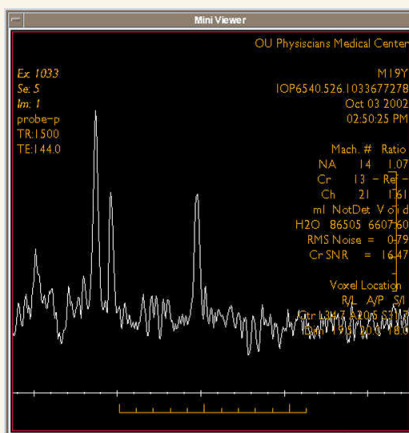
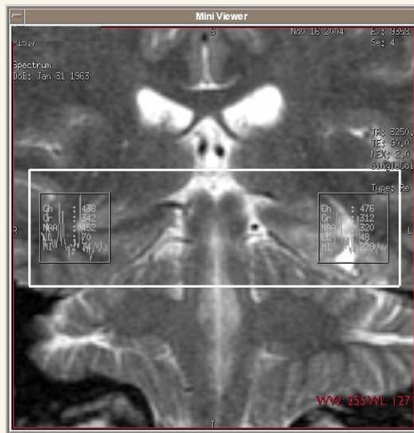
- Is a hereditary neurological condition that affects all ages. The name arises from the potato stem-shaped growths that occur in the brain, also known as tubers. These growths often involve overgrowth of nerves or the connective tissue within them.
- Tuberous Sclerosis can be **non-cancerous growths in the brain.**



Contralateral Evaluation



CSI and Single Voxel

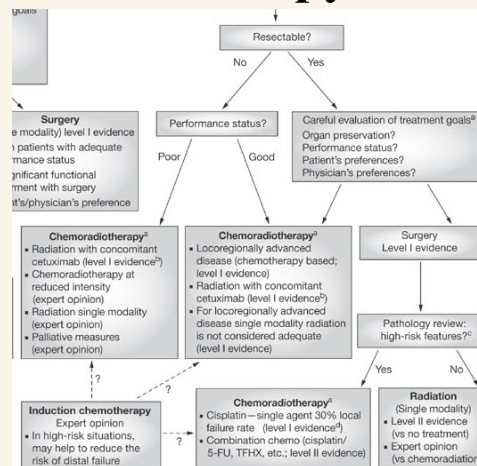


Clinical Decision (based on spectroscopy)


- The high **Cho/Cr ratio** is consistent with a high grade astrocytoma.
- Among primary brain tumors, malignant astrocytomas are the most common in all age groups. (However, among all brain tumors, metastases are the most common.) Few patients with **GBM survive longer than 3 years and only a handful survive 5 years**. Previously reported long-term survivors of GBM may be patients diagnosed with GBM who actually harbor low-grade glioma, pleomorphic xanthoastrocytoma, ganglioglioma, or other lesions.



Part 2a) Rapid advances in radiation therapy Chemo-radiation



From
Tanguy Y Seiwert, Joseph K Salama, Everett E Vokes.
Nat Clin Pract
Oncol:2007;4(3):156-171.



The University of Oklahoma
Health Sciences Center

General principles of concurrent chemoradiotherapy

- Balance Organ preservation vs. Curative Potential
- Which Agents?
- Single agent-based chemoradiotherapy
- Multiagent-based chemoradiotherapy

* Keep in mind how can we **Find**, **Forecast** and **Follow** the cancer???



The University of Oklahoma
Health Sciences Center

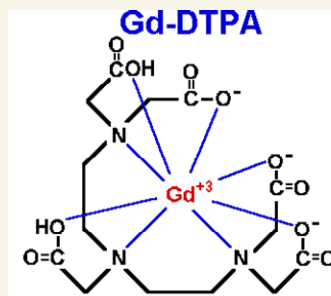
Current Trials

- Anti-EGFR therapies
(Maybe molecularly image, by tagging? – early research)
- Antiangiogenic agents
(maybe **functional imaging** can follow)

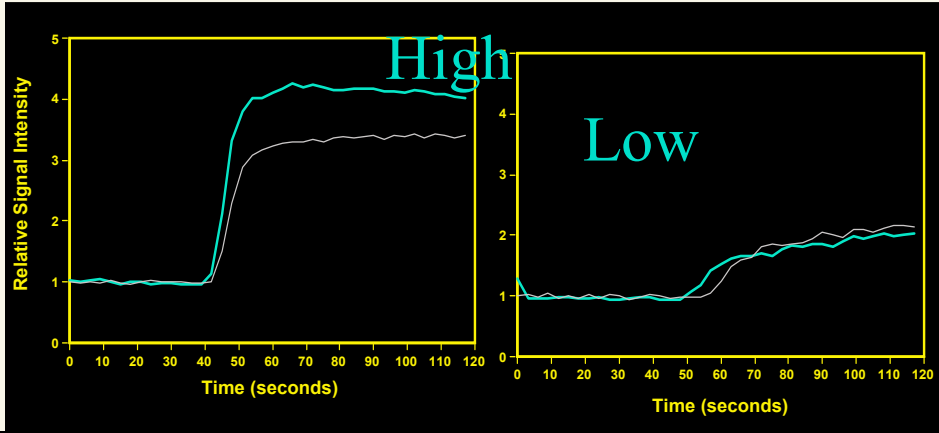


2c. Contrast Enhanced Imaging

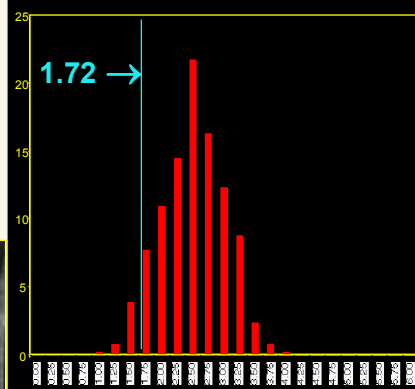
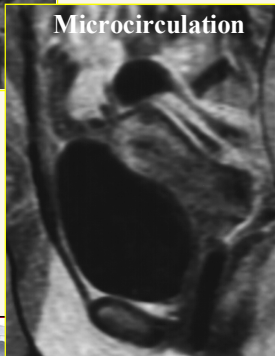
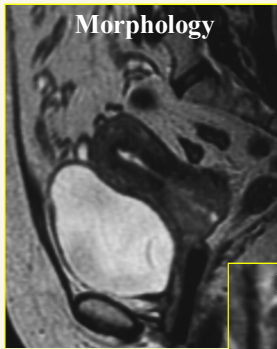
- MRI contrast agents affect the relaxation times of the water protons in nearby tissue
- Positive agents (T_1 relaxation agents)
 - Consist of 1 or more metal ions (Gd, Mn) that contain 1 or more unpaired electrons (paramagnetic) which reduces T_1 and increases T_1 signal intensity
 - Gd (gadolinium)-DTPA (diethylene triamine penta acetic acid)



Tumor Microcirculation Pattern (Dynamic Enhancement Pattern)



Dynamic Enh. Pattern: *Low*

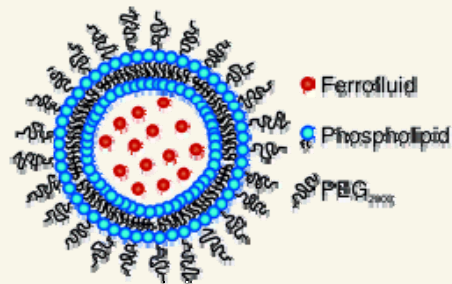


Outcome:
 Recurrence (2 mo.)
 Death (6 mo.)



Contrast Enhanced Imaging

- MRI contrast agents affect the relaxation times of the water protons in nearby tissue
- Negative agents (T_2 relaxation agents)
 - Shorten T_2 , and eliminate signal from tissue in area of interest
 - Superparamagnetic iron particulate complexes



Targeting Molecular Events

- Standard MRI procedures have helped somewhat with pathological diagnosis and lesion characterization to a certain extent, however there is a [lack of molecular-specific information](#)
- There is a need to develop better diagnostic approaches for the early detection of disease pathology
- Use [antigen-specific MRI molecular probes](#) for the *in vivo* detection of antigens



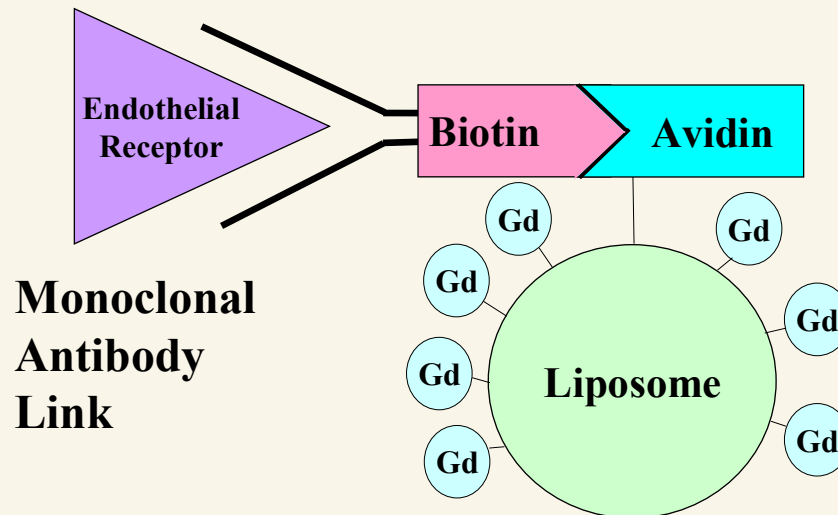
Molecular-Targeted Imaging

- Recently new and more powerful MRI technologies for specific **molecular targeting** or tagging have been developed
- Contrast agent MRI probe is targeted to a specific receptor or antigen by a monoclonal antibody (mAb) which binds with high affinity to the receptor or antigen
- This method is feasible for clinical diagnosis of diseases by characterizing specific molecular events associated with particular diseases



The University of Oklahoma
Health Sciences Center

Slide to replace slides 62 to 65



The University of Oklahoma
Health Sciences Center

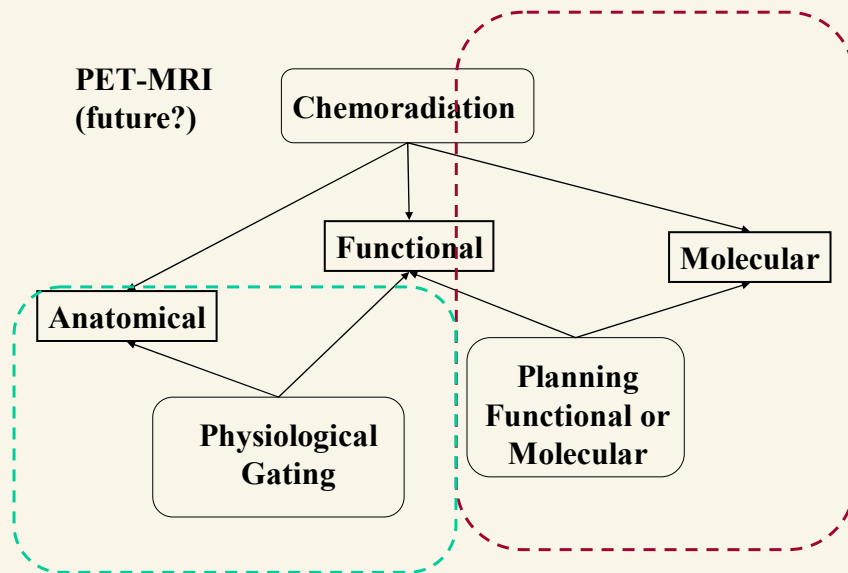
Part 3a) Hybrid modalities (primarily nuclear?)

- PET-CT / PET-SPECT



The University of Oklahoma
Health Sciences Center

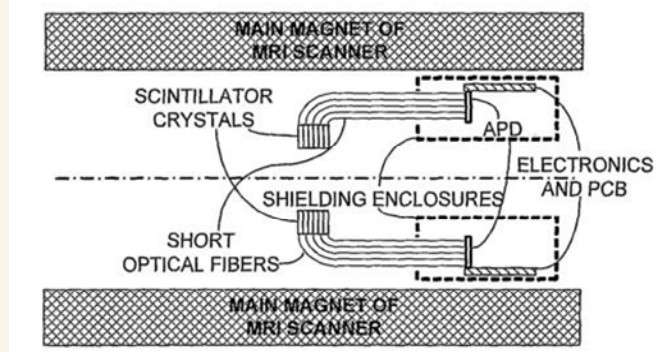
Birds Eye View: PET/CT



The University of Oklahoma
Health Sciences Center

Part 3b) Hybrid modalities (primarily nuclear?)

– PET-MRI (futures??)

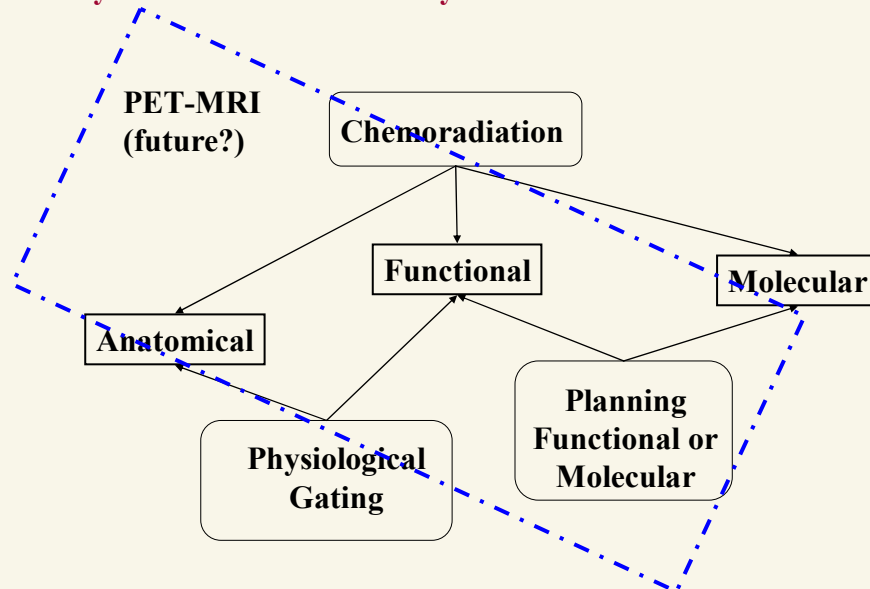


From Simon Cherry's Patent Pending [WO 2006/119085](#)



The University of Oklahoma
Health Sciences Center

Birds Eye View: PET/MRI – maybe in the future???



The University of Oklahoma
Health Sciences Center

PET-MRI Scanners: Further Evolution in Imaging

- Scanners that combine the capability of positron emission tomography (PET) with magnetic resonance imaging (MRI) are now in process of being developed.
- PET evaluates metabolic aspects of disease, while MRI provides anatomical information.
- The PET-MRI scanner is a further evolution of an earlier hybrid, PET-CT, which combines PET with computed tomography (CT) imaging.
- A hybrid PET-MRI scanner might also reduce errors due to a partial mismatch of images caused by variations in patient position in the separate scanners.



The University of Oklahoma
Health Sciences Center

Clinical Applications of PET-MRI Image Fusion

- “PET-MRI fusion has been used for the initial evaluation of brain tumors, as well as treatment planning and follow-up after therapy.”
- “Diagnosis with PET-MRI fusion has been associated with increased survival times for patients with recurrent high grade gliomas treated by radiotherapy, and with more specific diagnoses of brain tumours in children.”
- “The combined images provide additional information on the volume of the brain to be treated, permitting more complete destruction of the target lesion and potentially reducing adverse events associated with the treatment (surgery or radiotherapy).”

Schlyer D, Rooney W, Woody C, Vaska P, Kriplani A, Stoll S. Nuclear Science Symposium Conference Record 2004; IEEE Volume 6, Issue 16-22 Oct. 2004: 3419 – 3421.



The University of Oklahoma
Health Sciences Center


Development of a simultaneous PET/MRI scanner

•“The anatomical detail given by MRI and spectroscopy available with magnetic resonance spectroscopy (MRS) **complement** the quantitative physiological imaging with PET.”

•“Such a device has not become a reality because of the incompatibilities of photomultiplier tubes (PMTs) and their associated electronics with MRI's high magnetic fields, as well as significant constraints on PET camera size due to the limited patient port of MR scanners.”

•“Recent **advances in solid-state electronics** have opened the possibility of replacing photomultiplier tubes with avalanche photodiodes (APDs) that are compact and do not share the vulnerabilities of PMTs to magnetic fields.”

Schlyer D, Rooney W, Woody C, Vaska P, Kriplani A, Stoll S. Nuclear Science Symposium Conference Record 2004; IEEE Volume 6, Issue 16-22 Oct. 2004: 3419 – 3421.



The University of Oklahoma
Health Sciences Center

Outlining Some Basic Challenges

Part 1: Levels of observing cancer (by imaging)

- a) anatomical
- b) functional*
- c) molecular

*Also interpretation for staging such as lymphography

Part 2: Rapid advances in radiation therapy

- a) Chemo-radiation
- b) planning via functional/molecular
- c) physiological gating

Part 3: Hybrid modalities (primarily nuclear?)

- a) PET-CT / PET-SPECT
- b) PET-MRI (futures??)

** Two way street- Clinical Imaging and Animal Preclinical Imaging



The University of Oklahoma
Health Sciences Center

Thank you for your Attention
Future and Current Growth

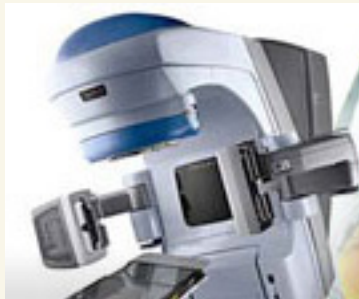

Planned is \$120 million OU Cancer Institute clinical research and treatment building at University of Oklahoma Health Sciences. (including a proton beam radiation treatment planning system)



The University of Oklahoma
Health Sciences Center

Part 2c) Advances in radiation therapy physiological gating



The University of Oklahoma
Health Sciences Center

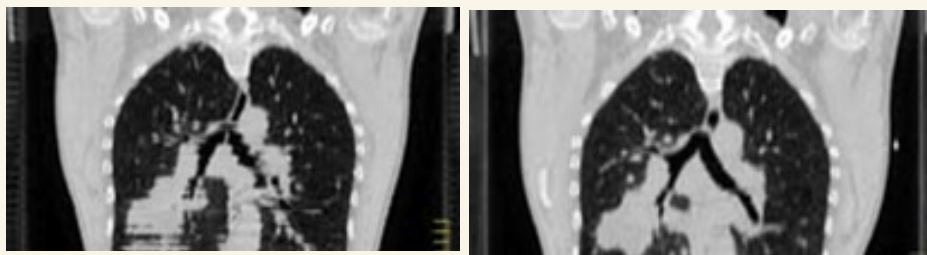
Respiration Control and Impact on RT

- **Respiration impacts tumors in the thorax and the abdomen.** More specifically, areas include, but are not limited to, the lung, breast, liver, pancreas, kidney and organs in the pelvis region, such as the prostate. With uncertainty not all gets delivered to target.
- **Respiratory gating is a synchronization of the radiation beam with the respiration motion.** This helps to deliver more accurately to the target and not as much to healthy tissue.



The University of Oklahoma
Health Sciences Center

From CT data from a patient with metastatic lung cancer
Medical College of Virginia via varian



• Ungated

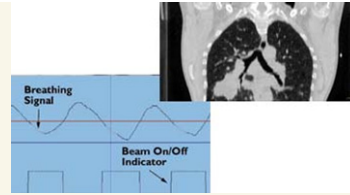
Gated



The University of Oklahoma
Health Sciences Center

Real-Time Position Management (RPM)

Respiratory Gating

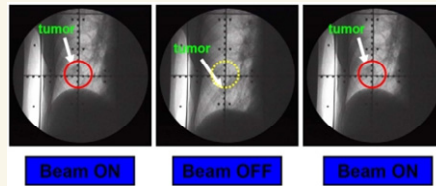


High-resolution conformal radiation therapy requires accurate localize the tumor and define the tumor contour. i.e. maximize the dose to the tumor and minimize the dose to surrounding sensitive normal tissue.

Unfortunately, physiological functions, such as normal respiration (without good gating), can cause a change in the tumor position during treatment, requiring the use of a larger treatment volume to compensate.



The University of Oklahoma
Health Sciences Center



- RPM Respiratory Gating system is designed to be used anywhere you encounter the **effects of respiratory motion**. First, the system uses a sophisticated video monitor to characterize the patient's breathing pattern. The pattern is obtained by tracking the motion of the lightweight, **retro-reflective marker placed on the patient**.
- Then through video image analysis and signal processing, the system identifies both the full range of chest wall motion during respiration and the normal pattern of that motion. By correlating this data with the motion of the tumor in simulation, **you can create a treatment plan that gates the treatment beam on only when the tumor falls within the planned beam aperture.**
- Slide from Varian



The University of Oklahoma
Health Sciences Center